

# Myofunctional Therapy

## A Novel Treatment of Pediatric Sleep-Disordered Breathing

Joy L. Moeller, BS, RDH<sup>a,\*</sup>,  
Licia Coceani Paskay, MS, CCC-SLP<sup>a</sup>,  
Michael L. Gelb, DDS, MS<sup>b</sup>

### KEYWORDS

• Myofunctional • Sleep • Breathing • Nasal • Tongue • Posture • Neuroplasticity • Assessment

### KEY POINTS

- Orofacial myofunctional therapy (OMT) is a noninvasive option for the treatment of sleep-disordered breathing (SDB) in children.
- OMT has the potential to become an important alternative to other available nonsurgical treatment modalities.
- Early identification and correction of mouth breathing are recommended as early as the first year of life.
- Removing the tonsils and adenoids does not always change the breathing pattern from oral to nasal, if the habit of mouth breathing has not been corrected.
- Myofunctional therapists use a variety of supportive techniques to promote self-awareness and positive habits and to prevent the dysfunctions that characterize pediatric SDB.

### INTRODUCTION

Orofacial myofunctional therapy (OMT) is defined as the treatment of dysfunctions of the muscles of the face and mouth, with the purpose of correcting orofacial functions, such as chewing and swallowing, and promoting nasal breathing. OMT has been used for many years to repattern and change the function of the oral and facial muscles and to eliminate oral habits, such as prolonged thumb-sucking and nail biting, tongue thrusting, open mouth at rest posture, incorrect mastication, and poor oral rest postures of the tongue and lips.<sup>1</sup> Physicians, dentists, and orthodontists have also

used myofunctional therapy as an adjunctive noninvasive treatment of temporomandibular joint disorders (TMJD).

In the last few years<sup>2,3</sup> myofunctional therapy has also been proposed as a potentially important component of the multidisciplinary treatment of obstructive sleep apnea (OSA). The use of OMT as a noninvasive option for the treatment of sleep-disordered breathing (SDB) in children in particular represents a new and novel application of this well-established therapeutic approach and has the potential to become an important alternative to other available nonsurgical treatment modalities, such as positive airway pressure and

---

Disclosures: Paid lecturer for the Academy of Orofacial Myofunctional Therapy (AOMT), personally related to the AOMT Managing Director a main shareholder, Marc Moeller; Vice-president of the Academy of the 501(c)3 Academy of Applied Myofunctional Sciences (AAMS) (J.L. Moeller); Licia Coceani Paskay is a paid lecturer for the AOMT and President of the 501(c)3 AAMS (L.C. Paskay); No conflicts of interest (M.L. Gelb).

<sup>a</sup> Academy of Orofacial Myofunctional Therapy (AOMT), 910 Via de la Paz #106, Pacific Palisades, CA 90272, USA; <sup>b</sup> Department of Oral Medicine and Pathology, Tufts University School of Dental Medicine, NYU, 635 Madison Avenue, 19th Floor B/W: 59th & 60th Street, New York, NY 10022, USA

\* Corresponding author.

E-mail address: [joyleamoeller@aol.com](mailto:joyleamoeller@aol.com)

Sleep Med Clin 9 (2014) 235–243

<http://dx.doi.org/10.1016/j.jsmc.2014.03.002>

1556-407X/14/\$ – see front matter © 2014 Elsevier Inc. All rights reserved.

oral appliances. This article outlines the development and clinical application of OMT, discusses the rationale for its application to SDB, and presents evidence supporting this treatment as it relates to prevention, assessment, and treatment of pediatric SDB.

## HISTORY OF OMT

The history of myofunctional therapy in the United States goes back to the early 1900s and parallels orthodontic treatment.<sup>4</sup> In the 1950s to 1960s, Walter Straub,<sup>5,6</sup> an orthodontist, wrote numerous articles on malfunctions of the tongue and abnormal swallowing habits and their relationship to orthodontics and speech. He thought a major cause of oral problems was bottle-feeding. Inspired by the work of Walter Straub, Roy Langer, Marvin Hanson, and Richard Barrett in the 1970s and 1980s, Daniel Garliner<sup>7,8</sup> was the first to recommend a therapeutic routine for nighttime sleeping consisting of keeping the lips together and the tongue up on the palate. Subsequently, 2 speech pathologists from Brazil, Irene Marchesan and Ester Bianchini, studied with Daniel Garliner in the 1980s and went back to Brazil, where they created a university program for speech pathologists centered on treating orofacial myofunctional disorders. Today, there are over 30 universities with PhD programs in myofunctional therapy and many programs that focus on sleep disorders and myofunctional therapy.

## RATIONALE: DEVELOPMENT OF THE UPPER AIRWAY

As man evolved to an upright posture, the larynx descended, the forebrain grew, and the facial framework retreated, as the nasal airway became diminished in size and function. This evolution is one reason humans do not have the olfactory ability of other mammals. As the cranial base angle flexed, the maxilla was compressed and the paranasal sinus size was reduced, creating millions of sinus sufferers as well as other facial changes.

The flattened maxilla and longer face is a relatively recent phenomenon seen in humans, differentiating man from primates. The decrease in nose volume associated with cranial base flexing may have increased high upper airway resistance and increased the potential for collapse further down in the oropharynx. Man was no longer an obligate nose breather, and with increased demands, mouth breathing was born. This trend of mouth breathing, downward migration of the tongue base and descent of the hyoid, is associated with retrognathic changes in mandibular

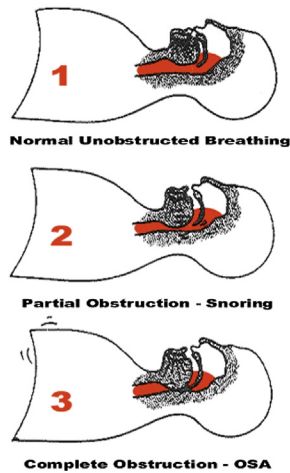
posture. The increase in mouth breathing is associated with less time spent with tongue to the palate, and therefore, with narrowing of the maxilla and an increased facial height. This downward and backward rotation of the maxilla and mandible is a powerful predictor of SDB as well as TMJD and malocclusion. A variety of researchers, clinicians, and anthropologists have identified an underdeveloped maxilla as being the root cause of malocclusion and naso-oropharyngeal constriction. Early identification of mouth breathing is therefore recommended as early as the first year of life.

Although the primary function of the genioglossus muscle is to protect the patency of the upper airway, an improper oral resting posture of the tongue will have a negative influence on the development of the oral cavity and the airway.<sup>9</sup> The anatomy of the upper airway in turn guides the growth and development of the nasomaxillary complex, mandible, temporomandibular joint, and ultimately, the occlusion of the teeth; thus, malocclusion and facial dysmorphism may be the result of compensation for a narrowed airway (Fig. 1).

## *Genioglossus Muscle Stabilizing the Airway*

There are several etiologic factors that have been linked in varying degrees to the development of SDB in children, which have implications for the potential utility of OMT as a therapeutic intervention; these implications include feeding methods, oral habits, craniofacial abnormalities, hypertrophic tonsils and adenoids, chronic mouth breathing sleep position, and restricted frenum. For example, bottle-feeding has been shown to be a major contributing factor to an anterior open bite in the primary dentition,<sup>10</sup> whereas overuse of spouted ("sippy") cups may also contribute to a low tongue-rest posture, thereby leading to a narrow high palate. Oral habits such as the habitual use of a thumb or pacifier may also lead to a low tongue rest posture and OMD. It has been noted that the frequency, intensity, and duration of oral habits and mouth-soothing devices may lead to OMDs. When the thumb or another object is in the mouth often and/or for a prolonged period of time, as a self-soothing strategy for example, it applies pressure against the palate, and the tongue may develop a low rest posture. Also, incorrect pressure exerted on the jaws may lead to airway problems and a TMJD. Other oral habits such as finger-sucking, nail biting, lip biting or licking, and tongue sucking may develop in infancy and persist into adulthood, leading to malocclusion.<sup>11</sup>

**Activity of the Genioglossus: Stabilizes and enlarges the portion of the upper airway that is most vulnerable to collapse (as in Sleep Disorders)**



**Fig. 1.** Genioglossus Muscle Stabilizing the Airways. (From Mathur R, Mortimore IL, Jan MA, et al. Effect of breathing, pressure and posture on palatoglossal and genioglossal tone. Clin Sci 1995;89:441–45; with permission.)



Mouth breathing or an open mouth at rest may be one cause of OMDs. If the mouth is open, the tongue usually rests down and forward. This position may cause an abnormal growth pattern, which may lead to a forward head and neck posture, malocclusion, and SDB.<sup>12</sup> Mouth breathing also involves lack of lip closure, which is necessary for jaw stability and to create the intraoral negative pressure necessary to hold the tongue in place. Moreover, in mouth breathing there is a lack of tongue-to-palate contact, necessary to create the “suction-cup” effect that holds the tongue in place and prevents it from falling into the pharynx.

Hypertrophic tonsils and adenoids may also lead to OMD and SDB. If the palatine tonsils are hypertrophic, the tongue is prevented from swallowing properly, forcing the tongue to come forward during the swallow and to rest forward and down. However, removing the tonsils and adenoids does not always change the breathing pattern from oral to nasal, especially in the long-term. A myofunctional therapist may be needed to assist the child in retraining the function of the tongue, in breathing, chewing, and swallowing, and to eliminate maladaptive oral habits. Finally, restricted lingual or labial frena may cause an OMD<sup>13</sup>; if the tongue is not able to create a vacuum seal on the palate, then a high and narrow palate may result, which is considered to be a risk factor for OSA (Fig. 2).<sup>14</sup>

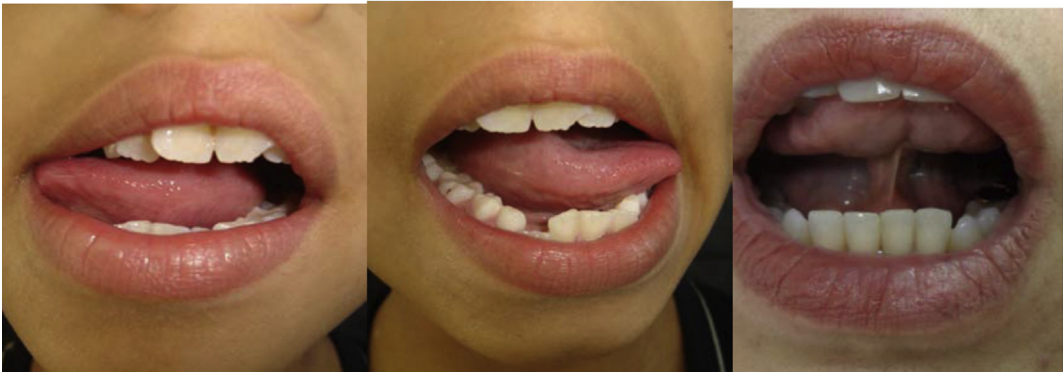Several studies support an empiric basis for myofunctional therapy in the treatment of SDB in adults. In an often-referenced study, Guimarães and colleagues<sup>15</sup> reported not only reduced symptoms of sleep apnea but also objective evidence of

decreased disease severity. The study reports that the apnea/hypopnea index (AHI) was reduced by 39% in those patients, after 3 months of myofunctional therapy. More recently, a series of studies on the application of myofunctional therapy of SDB in children from Stanford University showed that the addition of myofunctional therapy to adenotonsillectomy or palatal expansion reduced the risk of reoccurrence of SDB. A retrospective investigation by Guilleminault and colleagues<sup>3</sup> evaluated the application of myofunctional therapy along with adenotonsillectomy and orthodontic treatment. In patients who received myofunctional therapy, the AHI and the oxygen desaturation were normalized, whereas most subjects who did not receive myofunctional therapy experienced a relapse in both the AHI and the mean minimum oxygen saturation. The authors conclude that the absence of myofascial (myofunctional) treatment is associated with an increased risk of SDB recurrence.

Although studies that show a specific effect of myofunctional therapy on children’s sleep is relatively small, research supporting that OMT indeed normalizes the basic orofacial functions involved in SDB<sup>16,17</sup> is more robust. For example, Izu and colleagues<sup>18</sup> found that oral breathers were more likely to have snoring and OSAs and suffer from adenotonsillitis and otological symptoms. Cunha and colleagues<sup>19</sup> found that breathing abnormalities in children not only alter sleep but affect chewing and food intake. Normalizing orofacial functions in children also requires time. Marson and colleagues<sup>20</sup> demonstrated the effectiveness of an OMT program to normalize nasal breathing with peak results at 12 weeks, whereas Gallo and Campiotto,<sup>21</sup>

**Tongue mobility (best result = 0 e worst result = 14). Final result =**

	Successful	Partially successful	Unsuccessful
Protrude and retract	(0)	(1)	(2)
Touch the upper lip with the apex	(0)	(1)	(2)
Touch the right commissura labiorum	(0)	(1)	(2)
Touch the left commissura labiorum	(0)	(1)	(2)
Touch U&L molars	(0)	(1)	(2)
Apex vibration	(0)	(1)	(2)
Sucking against the palate	(0)	(1)	(2)



**Fig. 2.** Determining the need for a Lingual Frenectomy: Mobility Test.

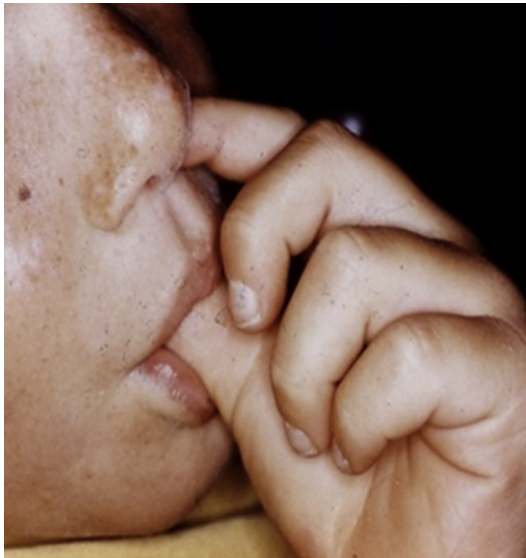using a similar protocol, found nasal breathing was normalized after about 10 sessions.

**CLINICAL ASSESSMENT**

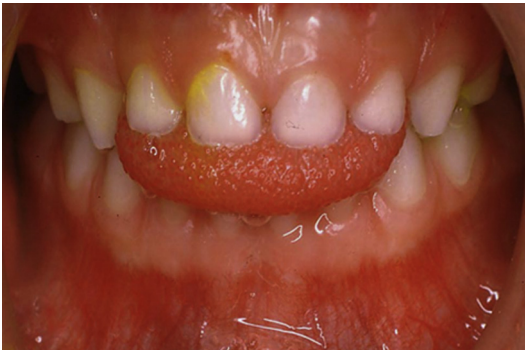Every health professional who works with patients with sleep disorders has different tools available for assessment, based on their needs, scope of practice, and preferences. Myofunctional therapists, as a multidisciplinary group of professionals, use various tools and practices, which often

overlap but retain some individual characteristics depending on the background of the therapist. Moreover, myofunctional therapists are trained to identify other underlying orofacial dysfunctions that are affected or are a contributing factor in sleep disorders.

As part of the standard evaluation, the orofacial myofunctional therapist takes a thorough medical and developmental history, with an emphasis on SDB risk factors. Important components of the assessment include identification of oral habits that interfere with a proper oral rest posture, recognition of the incorrect rest position of the tongue, determination of incorrect swallow, labial and lingual frenum restriction and inadequate lip seal, and evaluation of functional head and neck posture (after age 3–4 years) (Figs. 3–14).



**Fig. 3.** Thumb habit.



**Fig. 4.** Tongue thrust.



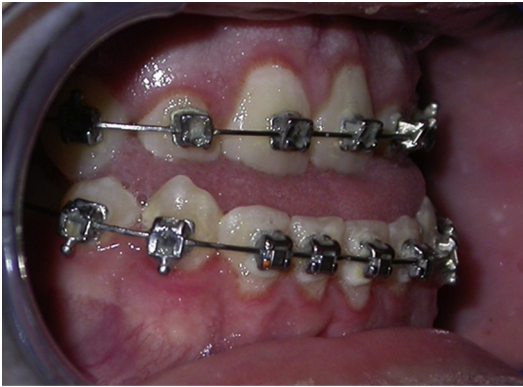

Fig. 5. Tongue rest position.

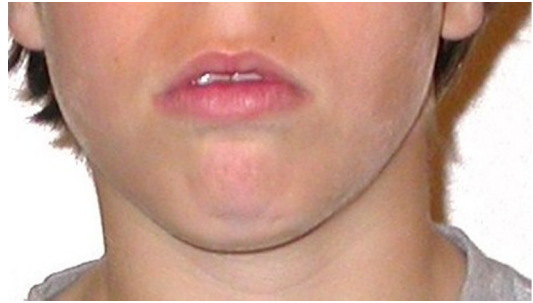


Fig. 8. Open lips at rest: may be flacid, swollen or cracked.

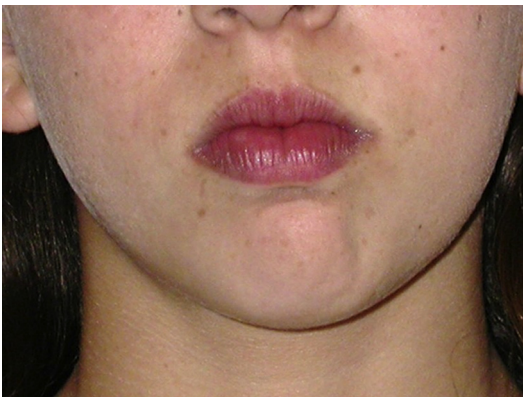

Fig. 6. Over-developed mentalis muscle.

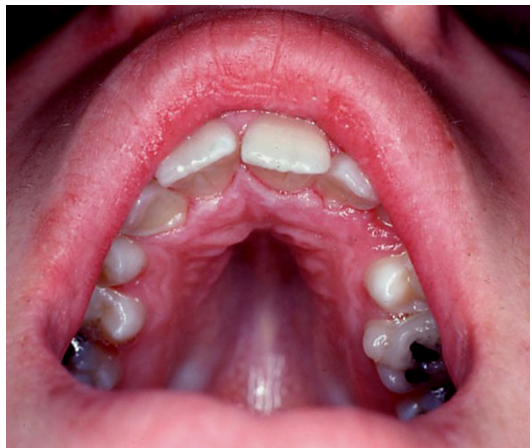

Fig. 9. High narrow palate.

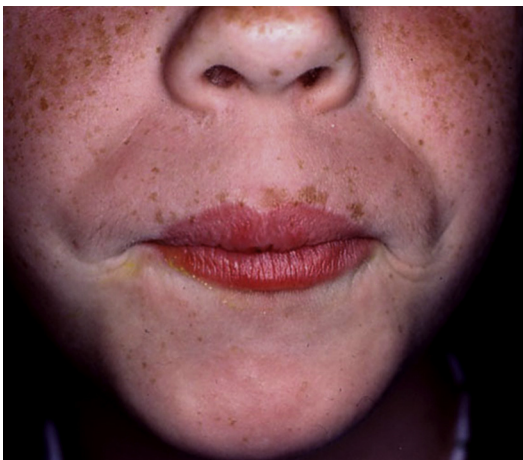

Fig. 7. Tense peri-oral muscles.



Fig. 10. Forward head posture.

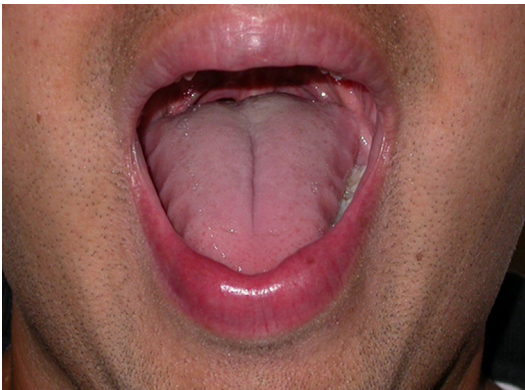

Fig. 11. Scalloped tongue.

**Treatment**

Treatment consists of habit elimination and behavior modification, jaw stabilization exercises, repatterning the oral facial muscles and changing their function for optimal nasal breathing, oral rest position, chewing, and swallowing. There are 4 basic components to the treatment:

1. Restoring Proper Rest Oral Posture

The first step is to educate the patient about problematic oral habits they may have and how to modify or eliminate the behavior, in terms of reduced frequency, duration, and the intensity of the habit. Myofunctional therapists use a variety of supportive techniques to allow the patient to first understand the damage being done and then to solicit a commitment to change, even in young children. Then, the patient is supported with rewards and positive reinforcement from both the family and the therapist. Therapists then will introduce

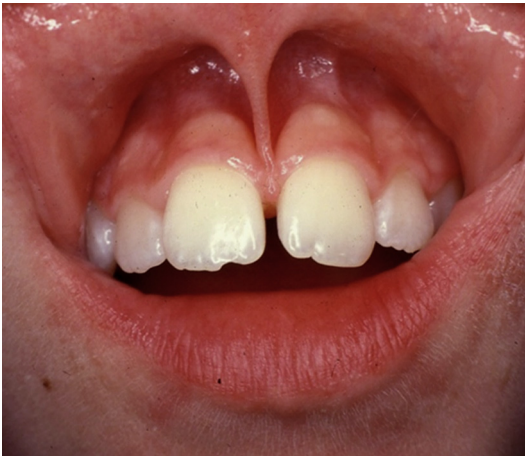

Fig. 12. Restricted labial and lingual frena.

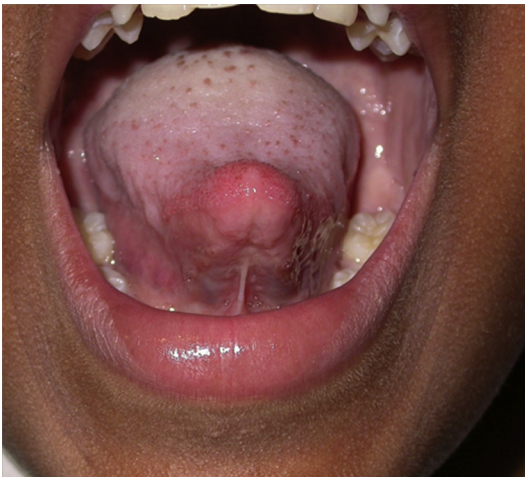

Fig. 13. Restricted labial and lingual frena.

diaphragmatic breathing and create a lip seal (in the absence of airway blockages or allergies), so that the lips are closed during the night. Therapy then continues with training the blade of the tongue to go to the “spot,” which is located posterior to the first rugae or ridge posterior to the maxillary central incisors on the palate. This therapy will also help to substitute the thumb with the tongue if necessary.

2. Repatterning of Facial Muscles

Next, the therapist will work with a sequential set of exercises to activate and then repattern the oral facial muscles. Therapists work with the muscles of mastication, which support the mandible and which

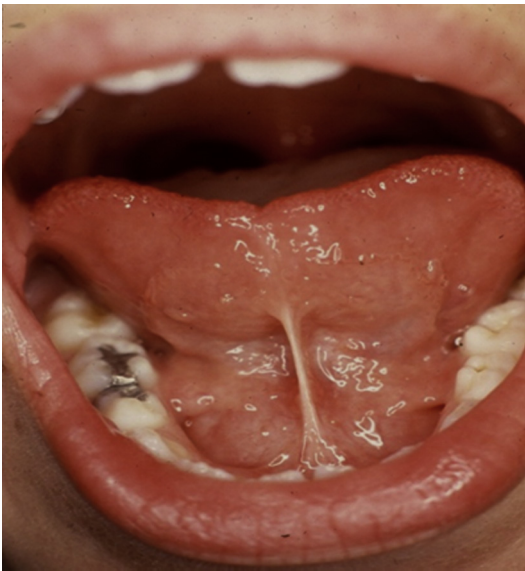

Fig. 14. Restricted labial and lingual frena.

aid the proper position of the genioglossus at night. Then, additional training addresses the orbicularis oris as well as the intrinsic and extrinsic tongue muscles, the buccinators, and the perioral muscles.

### 3. Teaching Proper Chewing and Swallowing

Next, proper chewing and swallowing is gradually introduced. Proper oral posture is reinforced even during sleep, with subconscious auto-suggestion and biofeedback. Success is evaluated using the Mallampati score, the grade of tongue scalloping, relaxation, or activation of the perioral muscles, as well as attaining a lip seal and palatal tongue rest position during both the day and the night.

### 4. Functional posture training

Myofunctional therapists are trained to promote a functional head position during sleep, to avoid the jaw being in close proximity to the chest because this position may contribute to SDB. Also, OMTs instruct patients to hold an upright head and neck posture, especially during the swallowing process.

If myofunctional therapists suspect that the “tongue-tie” (or lip-tie) is contributing to a child’s SDB, they will evaluate both the labial and the lingual frena, usually after a few weeks of exercises to ensure that full range of motion of the tongue and lips is possible. If the restriction remains, the patient is referred to a physician or dentist who is comfortable doing the surgery. After the release, the patient must immediately do exercises to assure proper function of the tongue. Otherwise, more revisions may be required.

The key to successful treatment is to establish a rapport with the pediatric patient and the caregiver and to motivate and monitor the outcome on a weekly basis for several months and then gradually reduce the frequency of appointments to once a month. The therapist must also enlist the assistance of the parent or caregiver to become the “therapist” at home to assure a successful result.

Because myofunctional therapy relies on active patient participation, OMTs use several techniques that are based on the 10 principles of neuroplasticity.<sup>22</sup> Neuroplasticity means the ability of the brain to change, following physiologic or pathologic input, generating an adaptive response. These principles include the following.

#### ***Use it or lose it***

In general, because muscle function requires energy, if the muscles are not properly used, the

brain stops or reduces nourishing those muscles and hypotonia may follow. Two studies<sup>23</sup> indicated that loss of prolonged sensory input translates to a reduction of the somatocortical representation, such as in children with a habitual open mouth during the day and at night.

#### ***Use it and improve it***

Myofunctional therapy revolves around the principle of improving a function through repetition, metacognition, and awareness. For example, the tongue is repositioned and trained to contact the palate comfortably, thus providing the natural negative pressure (suction) that keeps the tongue, and especially the genioglossus, in the proper position during sleep.<sup>15,24</sup>

#### ***Plasticity is experience specific***

This principle suggests that the success of some therapy protocols for sleep disorders<sup>15</sup> relies on targeting the very muscles that are hypofunctioning at night, such as the soft palate, tongue, and pharyngeal walls.

#### ***Repetition matters***

“Practice” improves performance by creating, maintaining, and expanding new neural areas corresponding to the new behavior. In myofunctional therapy repetition is paramount so that a new behavior, such as the tongue position or lips closure, is rehearsed every day and every evening until the new habit is formed.

#### ***Intensity matters***

Ideally, patients should practice neuromuscular exercises every day; otherwise, the intensity of the neuromuscular change does not generalize to the night hours.

#### ***Time matters***

According to Fisher and Sullivan,<sup>16,25</sup> the training modality that is most effective is protracted and continuous, as opposed to brief and intermittent. Therefore, patients may need to be kept in therapy or follow-up mode for a prolonged period of time (usually 1 year, but 2 years is better for habituation).

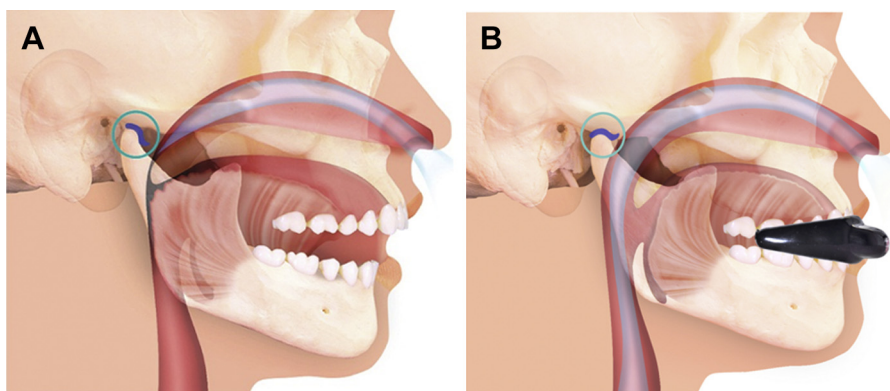
#### ***Saliency matters***

The need to motivate the patient by increasing the saliency or importance of therapy is a central element, because the higher the motivation and understanding of the reason some exercises need to be performed daily, the more likely the patient will perform the exercises prescribed.

#### ***Age matters***

Children are in the best condition to transform sensory-motor inputs into correct functions and





**Fig. 15.** (A) and (B) Airway Centric™ Philosophy.

make them a life-long habit. In children, not only is neuroplasticity at its best but also muscles and soft tissues drive the development of bones through principles of the functional matrix and epigenetic influences.<sup>17,26</sup>

### **Transference**

The transference principle supports the co-occurrence of multiple functions when an overlapping one has been established.<sup>27</sup> When the patient breathes well through the nose, other functions can now easily take place even if they were hampered before, such as tongue repositioning or lip seal.

### **Interference**

When a patient learns a new behavior (such as nasal breathing), the old behavior (such as oral breathing) has the ability to interfere neurologically with the establishment of the new one. It is only by continuous repetition of the new behavior and suppression of the old one that plasticity occurs.

Because a transition from daily myofunctional retraining to nocturnal activities, when the brain is not directly engaged, requires a good degree of patience and perseverance, building motivation relies on the skills of the therapist. Motivation assists the development of habituation, which is a function of time (now, later, or in the future). In therapy, feedback must be used constantly, be it visual, auditory, or tactile. Therapy implies self-talk, but a visual reminder or touch stimulus may be needed as well.

Myofunctional therapy alone may be successful in treating mild-to-moderate SDB, but in many children with SDB, the best results are achieved with a combination of patient myofunctional retraining and other therapeutic options, such as adenotonsillectomy, oral appliances, or positive airway pressure (Fig. 15). Although more research is needed to document the effectiveness of OMT in

the treatment as well as the prevention of SDB in the pediatric population, the potential benefits of including a myofunctional therapist in a team approach should not be underestimated.

### **REFERENCES**

1. Hanson ML. Orofacial myofunctional therapy: historical and philosophical considerations. *Int J Orofacial Myology* 1988;14(1):3–10.
2. Huang YS, Guilleminault C. Pediatric obstructive sleep apnea and the critical role of oral-facial growth: evidence. *Front Neurol* 2013;3:184. <http://dx.doi.org/10.3389/fneur.2012.00184> (18).
3. Guilleminault C, Huang YS, Monteyrol PJ, et al. Critical role of myofascial reeducation in pediatric sleep-disordered breathing. *Sleep Med* 2013;14(6):518–25.
4. Levrini A, Favero L. The masters of functional orthodontics. Carol Stream (IL): Quintessence Publishing Co; 2003.
5. Straub WJ. Malfunction of the tongue. Part I. The abnormal swallowing habit: its causes, effects, and results in relation to orthodontic treatment and speech therapy. *Am J Orthod* 1960;46:404–24.
6. Straub WJ. Malfunction of the tongue. Part II. The abnormal swallowing habit: its causes, effects, and results in relation to orthodontic treatment and speech therapy. *Am J Orthod* 1961;47:596–617.
7. Garliner D. Myofunctional therapy in dental practice: abnormal swallowing habits: diagnosis-treatment. Brooklyn (NY): Bartel Dental Book Company, Inc; 1971.
8. Garliner D. Myofunctional therapy. Philadelphia: W. B. Saunders; 1976.
9. Mathur R, Mortimore IL, Jan MA, et al. Effect of breathing, pressure and posture on palatoglossal and genioglossal tone. *Clin Sci* 1995;89:441–5.
10. Romero CC, Scavone-Junior H, Garib DG, et al. Breastfeeding and non-nutritive sucking patterns related to the prevalence of anterior open bite in



- primary dentition. *J Appl Oral Sci* 2011;19(2):161–8.
11. Quashie-Williams R, daCosta OO, Isiekwe MC. Oral habits, prevalence and effects on occlusion of 4-15 year old school children in Lagos, Nigeria. *Niger Postgrad Med J* 2010;17(2):113–7.
  12. Bonuck KA, Chervin RD, Cole TJ, et al. Prevalence and persistence of sleep disordered breathing symptoms in young children: a 6-year population-based cohort study. *Sleep* 2011;34(7):875–84.
  13. Northcutt M. Overview the lingual frenum. *J Clin Orthod* 2009;18:557–65.
  14. Kushida C, Efron B, Guilleminault C. A predictive morphometric model for the obstructive sleep apnea syndrome. *Ann Intern Med* 1997;127(8 Pt 1):581–7.
  15. Guimarães KC, Drager LF, Genta PR, et al. Effects of oropharyngeal exercises on patients with moderate obstructive sleep apnea syndrome. *Am J Respir Crit Care Med* 2009;179(10):962–6. <http://dx.doi.org/10.1164/rccm.200806-981OC>.
  16. Silva LM, Aureliano FT, Motta AR. Speech therapy in the obstructive sleep apnea-hypopnea syndrome: case report. *Rev. CEFAC* 2007;9(4):490–6. <http://dx.doi.org/10.1590/S1516-18462007000400009>.
  17. Landa PG, Suzuki HS. Sleep obstructive apnea-hypopnea syndrome and the phonaudiological focus: literature review. *Rev. CEFAC* 2009;11(3):507–15. <http://dx.doi.org/10.1590/S1516-18462009000300020>.
  18. Izu SC, Itamoto CH, Pradella-Hallinan M, et al. Obstructive sleep apnea syndrome (OSAS) in mouth breathing children. *Braz J Otorhinolaryngol* 2010;76(5):552–6. <http://dx.doi.org/10.1590/S1808-86942010000500003>.
  19. Cunha DA, da Silva GA, Motta ME, et al. Mouth breathing in children and its repercussions in the nutritional state. *Rev CEFAC* 2007;9(1):47–54. <http://dx.doi.org/10.1590/S1516-18462007000100007>.
  20. Marson A, Tessitore A, Sakano E, et al. Effectiveness of speech and language therapy and brief intervention proposal in mouth breathers. *Rev CEFAC* 2012;14(6):1153–66. <http://dx.doi.org/10.1590/S1516-18462012005000054>.
  21. Gallo J, Campiotto AR. Myofunctional therapy in children with oral breathing. *Rev CEFAC* 2009;11(Suppl 3):305–10. <http://dx.doi.org/10.1590/S1516-18462009000700005>.
  22. Robbins J, Butler SG, Daniels SK, et al. Swallowing and dysphagia rehabilitation: translating principles of neural plasticity into clinically oriented evidence. *J Speech Lang Hear Res* 2008;51(1):S276–300. [http://dx.doi.org/10.1044/1092-4388\(2008/021\)](http://dx.doi.org/10.1044/1092-4388(2008/021)).
  23. Merzenich MM, Kaas JH, Wall JT, et al. Progression of change following median nerve section in the cortical representation of the hand in areas 3b and 1 in adult owl and squirrel monkeys. *Neuroscience* 1983;10:639–65.
  24. Engelke W, Jung K, Knosel M. Intra-oral compartment pressures: a biofunctional model and experimental measurements under different conditions of posture. *Clin Oral Investig* 2011;15(2):165–76.
  25. Fisher BE, Sullivan KJ. Activity-dependent factors affecting poststroke functional outcomes. *Top Stroke Rehabil* 2001;8(3):31–44.
  26. Moss M. The functional matrix hypothesis revisited. 1. The role of mechanotransduction. *Am J Orthod Dentofacial Orthop* 1997;112(1):8–11.
  27. Kleim JA, Jones TA. Principles of experience-dependent neural plasticity: implications for rehabilitation after brain damage. *J Speech Lang Hear Res* 2008;51(1):S225–39.