



CLINICAL REVIEW

Pediatric sleep-disordered breathing: New evidence on its development



Christian Guilleminault*, Farah Akhtar

Stanford University Sleep Medicine Division, Stanford Outpatient Medical Center, Redwood City, CA, USA

ARTICLE INFO

Article history:

Received 14 April 2014

Received in revised form

7 November 2014

Accepted 26 November 2014

Available online 4 December 2014

Keywords:

Pediatrics

Sleep-disordered breathing

Craniofacial development

Functional impairment

Genetic involvement

SUMMARY

Sleep-disordered breathing (SDB) in children could be resolved by adenotonsillectomy (T&A). However, incomplete results are often noted post-surgery. Because of this partial resolution, long-term follow-up is needed to monitor for reoccurrence of SDB, which may be diagnosed years later through reoccurrence of complaints or in some cases, through systematic investigations. Children undergoing T&A often have small upper airways. Genetics play a role in the fetal development of the skull, the skull base, and subsequently, the size of the upper airway. In non-syndromic children, specific genetic mutations are often unrecognized early in life and affect the craniofacial growth, altering functions such as suction, mastication, swallowing, and nasal breathing. These developmental and functional changes are associated with the development of SDB. Children without genetic mutations but with impairment of the above said functions also develop SDB. When applied early in life, techniques involved in the reeducation of these functions, such as myofunctional therapy, alter the craniofacial growth and the associated SDB. This occurs as a result of the continuous interaction between cartilages, bones and muscles involved in the growth of the base of the skull and the face. Recently collected data show the impact of the early changes in craniofacial growth patterns and how these changes lead to an impairment of the developmental functions and consequent persistence of SDB. The presence of nasal disuse and mouth breathing are abnormal functions that are easily amenable to treatment. Understanding the dynamics leading to the development of SDB and recognizing factors affecting the craniofacial growth and the resulting functional impairments, allows appropriate treatment planning which may or may not include T&A. Enlargement of lymphoid tissue may actually be a consequence as opposed to a cause of these initial dysfunctions.

© 2014 Elsevier Ltd. All rights reserved.

Introduction

Sleep-disordered breathing is related to upper airway collapse during sleep. In order to appreciate how this collapse occurs, it is important to have an understanding of the development and anatomy of the upper airway. The size of the upper airway and factors contributing to its narrowing can lead to increased risk of collapse and subsequent abnormal breathing during sleep. Because the upper airway is located below the skull and behind the face, any developmental changes in either of these two structures will impact the size of the upper airway. Facial growth is relatively rapid

early in life. At birth, the face represents one-seventh of the craniofacial structures and 50% by 20 y of age. Eighty percent of this development is reached early in life, by the age of 5–6 y [1]. The two facial components that are key in determining the size of the upper airway are the naso-maxillary complex and the mandible.

The development of the craniofacial structures

The naso-maxillary complex is located at the anterior part of the skull, and its growth has been classified by Bjork [2] according to age. From infancy until the toddler period, growth is 1 mm/y. During the prepubertal period (5–11 y), growth slows down to 0.25 mm/y and then accelerates again during the peripubertal period (12–17 y) to 1.5 mm/y. Maximal growth is thus seen early in life and during puberty.

Facial growth is influenced during the fetal period by the brain growth and in humans, particularly by the vast development of the

* Corresponding author. Stanford University Sleep Medicine Division, Stanford Outpatient Medical Center, 450 Broadway, MC5704, Redwood City, 94063 CA, USA. Tel.: +1 650 723 6601; fax: +1 650 721 3465.

E-mail address: cguil@stanford.edu (C. Guilleminault).

Abbreviation

AASM	American Academy of Sleep Medicine
AHI	apnea–hypopnea index
Ba–S–N angle	basion-sella-nasion angle (also called “sphenoidal angle”)
BAT	brown adipose tissue
Ba	basion
BMP4	bone morphogenic protein-4
EDS	Ehlers Danlos syndrome
EEG	electro-encephalogram
FGF8	functional growth factor-8
GA	gestational age
Msx1	muscle segment homeobox-1 (gene)
N	nasion
OSA	obstructive sleep apnea
PSG	polysomnogram
SDB	sleep-disordered breathing
S	sella turcica
T&A	adenotonsillectomy
WAT	white adipose tissue

frontal lobe. The growth of the brain is critical in the development of the face. As indicated by Enlow and Poston [3], there is a distinct angle between the vertical axis of the brainstem and the spinal cord, known as the nevrax, and the cortical regions. This angle is more or less obtuse and impacts the development of the face and features distinct to the ethnic differences seen between Caucasians and Far-East Asians [4]. Genetics also play a role in the growth of the brain and thereby the skull and its base which then impact the size of the upper airway. This association is clearly demonstrated in that the posterior width of the middle fossa of the skull is the exact lateral size of the erect and awake adult pharynx. The development of these structures further defines the relationship between the maxilla and the mandible, categorizing subjects either as “Class II” or “Class III”, based on their relative position to each other in addition to the upper and lower teeth. A Class II malocclusion refers to a retrognathic abnormal posterior positioning of the maxilla or mandible, particularly the mandible, relative to the facial and soft tissue structures. The mesiobuccal cusp of the upper first molar is not aligned with the mesiobuccal groove of the lower first molar and instead sits anterior to it. Conversely, a Class III malocclusion is prognathic with the upper molars posterior to the mesiobuccal groove of the mandibular first molar.

The interaction between the development of the naso-maxillary complex and support of the head in an individual with vertical posture is a critical adjustment. The extremity superior and posterior of the odontoid must be aligned, and this involves exact placement of the speno-palatine suture, the anterior part of atlas, and the superior limit of the odontoid. The speno-palatine suture involves the “sphenoidal angle” (Ba–S–Na) and the position of the naso-maxillary complex, i.e., the face. The sphenoidal angle can be easily traced on lateral cephalometry that is obtained in standardized conditions fixing the head in a defined position through usage of a cephalostat. Three structures easily recognizable on this form of imaging are the sella turcica (S), the nasion (N) and the posterior base of skull (basion-B). The Ba–S–N angle in a normal adult, is about 120°, although this measurement varies based on several factors including ethnicity. Delaire [5] defined a segment of this angle, the line from S to B, as C4. Calculation of the position of the superior and posterior part of the odontoid in relation to the two other landmarks in the occipital hole (anterior part of atlas and

speno-palatine suture) allows to determine abnormal positioning of the odontoid. Any abnormalities in the development of this crucial junction may lead to well-known neurological syndromes such as hydrocephaly, Arnold-Chiari, Dandy-Walker and other conditions typically associated with abnormal breathing dominant during sleep. The placement of the face and the development and adjustment of the naso-maxillary complex is vital in maintaining the crucial protection of the neuro-vascular structures below the cerebellum. This complex interaction between growth of the face and the posterior skull-base is again a consequence of being erect and having a relatively large brain to support in this erect position (Fig. 1).

The development of the face is thus a very closely regulated event, with continuous interaction between the development of the entire brain, the skull, and the skull-base.

The growth of the transversal portion of the naso-maxillary complex is influenced by three factors, the development of the nasal fossae during fetal life, the growth of the ocular cavities related to ocular development during fetal life, and the activity of the inter-maxillary suture that utilizes an enchondral mode of ossification and is active until about 16 y of age and undergoes complete synostose by the age of 25 y. The face is located at the anterior most point of the skull-base and is therefore especially dependent on the processes involved in its growth with maxilla and mandible been “pushed forward” by the development of the skull-base.

Development of skull-base and naso-maxillary complex

Genetic factors are critical in such development. Most of the growth of the skull-base is cartilaginous growth, and growth occurs in relation to “synchondroses” [6]. These serve as the site of bone growth in the skull-base and are located in the sutures between the

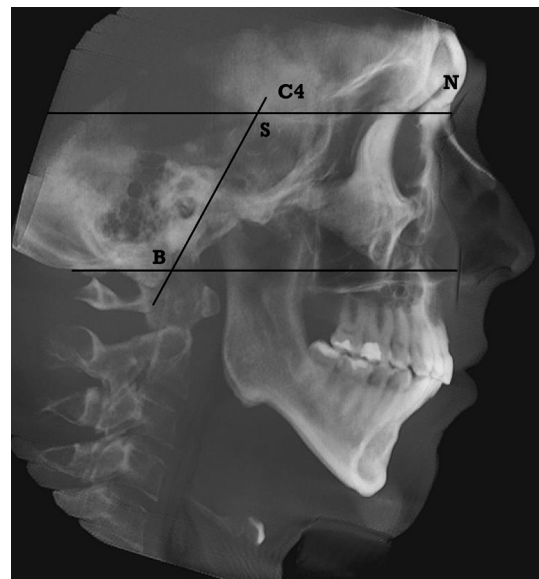


Fig. 1. Cephalometric X-ray with indication of basion-sella-nasion angle and “lines” investigated to evaluate position of odontoid and occipital hole. Basion-sella-nasion – Ba–S–Na-angle, also called sphenoidal angle is related to the vertical growth of the skull base and it is under the control of the speno-occipital synchondrose. This suture brings the occipital hole in a lower position. The movements of the occipital and sphenoid bones are important as there must be an adjustment with a position tangent to the tip of the odontoid. The craniocervical junction and the hard palate orientations are dependent on the speno-occipital synchondrose and on its flexion. Placement of the anterior spinal spine, of the hard palate, of the naso-maxillary complex and the skeletal class will have an impact on the width and placement of the hard palate and the size of the upper airway.

bones forming the skull and the skull-base. Synchondroses undergo three stages of growth and are particularly active during the “chondro-synostose” phase and early in life up to 5 y of age. If they are not stimulated, they may not induce growth. The sphenosphenoidal chondrose is responsible for the vertical growth of the skull base. It has an oblique direction and lowers the location of the occipital lobe thereby affecting facial growth. The growth of the naso-maxillary complex is related not only to the sphenoido-occipital synchondrose but also to the activity of the synchondrose of the skull base and particularly the cleft at the following sutures: inter-malar, inter-maxillary, inter-palatine, maxillo-malar, and temporo-malar.

It is important to note that the inter-maxillary suture is active postnatally as mentioned above, and is influenced by specific functions, such as suction, mastication, swallowing, and nasal breathing. These functions mobilize the facial muscles that play a clear role in facial growth.

The development of these functions is influenced by the quality of nasal respiratory roles, dental development which involves the position and height of alveoli and teeth position, and the activity and strength of the tongue and facial muscles. These facial muscles include the labial muscles, which influence not only the facial growth but also the position and height of the hard palate. As mentioned previously, the vertical growth of the naso-maxillary complex is related to the activity of the posterior skull base but also to that of the frontal-malar, frontal-maxillary, and maxillo-malar sutures. It is also related to the position of the hard palate and the alveolo-dental activity [6].

Mandibular development

While the mandible is also involved in the space controlling the size of the upper airway, it is independent of the base of skull and instead associated with the cervico-thoraco-digestive axis. This structure involves many muscle and ligament attachments and dictates head posture. It has both membranous and enchondral growth. The mandible is comprised of two parts, the condyle and the body. Although both these parts determine the upper airway size, the condyle plays a significantly more important role.

Genetic factors influence mandibular development in fetal life; other factors, however, are involved after birth. Trauma impacting the condyle's function as a joint can occur in a variety of ways, such as from a vaginal delivery using or even not using forceps, from a fall, or from inflammation due to disorders such as juvenile idiopathic arthritis [7]. This disorder impairs growth through rapid ossification of the joint. Any changes in the position of the condyle will cause the growth region to migrate. An example of this is apparent in cases in which chronic buccal (mouth) respiration develops. The position of the condyle in the articulation changes, and therefore the growth location also changes, transferring cartilaginous production more posteriorly. This will alter the incline at which bone grows causing a posterior mandibular rotation during youth development and leading to narrowing of the upper airway.

Three phases exist in the condylar growth and activity: *Phase 1*: fetal and early postnatal life where the suction function will be vital to the postnatal growth. *Phase 2*: 1–20 y of age where the mastication function influences growth and there is a progressive but clear decrease in growth role. *Phase 3*: the joint no longer has a growth role [6].

The role of two synchondroses active postnatally: the inter-maxillary and alveolo-dental synchondroses

Genetic abnormalities affecting membranous and cartilaginous craniofacial growth can lead to obvious malformation syndromes associated with sleep-disordered breathing (SDB) such as Apert,

Crouzon or Traecher-Colin syndromes [8]. In these disorders, abnormal breathing during sleep is recognized early in life.

However, in genetic impairments of endochondral growth leading to SDB, recognition is often delayed until after childhood. Ehlers Danlos syndrome (EDS) [9] is secondary to either an autosomal dominant, autosomal recessive, or X-linked mutation of genes located on proteins or enzymes, most commonly COL-1A1, COL 5A1, or 5A2. Several degrees of Ehlers Danlos syndrome have been described in humans, with one form not commonly recognized until adulthood as it manifests only with hyperextensibility of articulations and development of SDB. SDB may lead to complaints, but because the clinical symptoms are more of poor sleep, insomnia, daytime fatigue, rarely parasomnias, and attention difficulties in school or at work, they may not immediately be recognized as obstructive breathing during sleep. Regular evaluation of young family members of an adult case may uncover abnormal breathing during sleep when systematic polysomnography (PSG) is performed. In a report of our recently seen cases [9], clinical symptoms were as those mentioned above, with the most significant PSG finding being the degree of flow limitation [10,11] during total sleep time more so than the apnea–hypopnea index (AHI). Clinical evaluation again demonstrated the presence of an abnormally long face, narrow and high hard palate, and frequently associated cross-bite. While initially only abnormalities of the naso-maxillary complex may be seen, as patients enter adulthood and develop worsening SDB, defects of the condyle may also be found Fig. 2.

The syndromic EDS with cardiac or other systemic complication and more importantly, the often unrecognized non-syndromic cases with only hyperlaxity, demonstrate that impairment of the normal naso-maxillary complex and mandibular growth during fetal life leads to abnormal breathing during sleep in childhood.

The alveolo-dental synchondroses

When teeth are absent or are extracted in early life during their growth, this can lead to bone retraction and affect the facial growth. Over the past seven years, we have collected data on 257 individuals of age 14–30 y, who underwent extraction of wisdom teeth and had associated symptoms of obstructive breathing during sleep. These patients had documented flow limitation [10,11] between 50 and 90% of total sleep time and presence of obstructive sleep apnea (OSA) with a mean apnea–hypopnea index (AHI), as

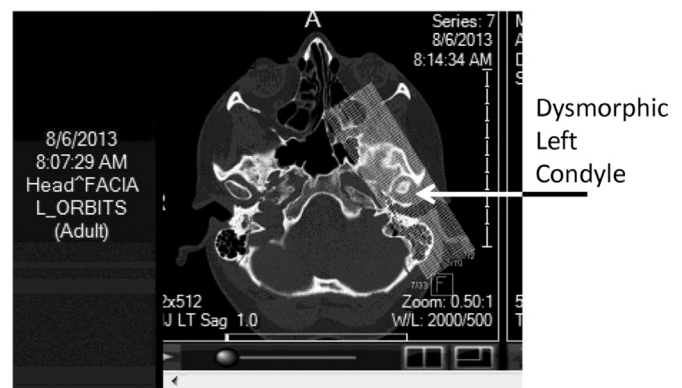


Fig. 2. Dysmorphia of the mandibular condyle in an 18 y old Ehlers Danlos Type III patient (a genetic cartilage impairment). This CT-scan allows studying the impairment of the mandibular condyle. Patient misdiagnosed for years: repetitive ankle luxations and temporo-mandibular pain with bruxism, presence of daytime fatigue, some degree of daytime sleepiness, difficulty to concentrate, and mandibular pain. Results of polysomnography: apnea–hypopnea index-AHI = 16.9 events/hour of sleep, lowest oxygen saturation: 89%, flow limitation: 85% of total sleep time.

defined by the American Academy of Sleep Medicine (AASM)–2013 [12], of 7.5 ± 2.3 events/h.

During this initial investigation, it was revealed that some of these patients had prior recognition of wisdom teeth agenesis. After this discovery, a systematic search was done to retrospectively analyze, through collaboration with an orthodontist, an association between teeth agenesis and presence of OSA in non-syndromic children seen during the prior five years. Forty-one cases were found. Dental agenesis is linked to genetic mutations with a dental homeo-code for agenesis of canine, incisive, and molar teeth. These mutations involve certain transcription factors as demonstrated in mice investigations [13]. We identified varying degrees of agenesis of the molar, incisive, and canine teeth. Independent of the degree of dental agenesis, all 41 subjects, aged 4–14 y, referred to an orthodontist office for their teeth agenesis and not for any symptom associated with sleep-disordered breathing, presented with abnormal breathing during sleep with associated flow limitation for more than 50% of total sleep time, a mean AHI of 7.3 ± 2 , and a mean minimum oxygen saturation of $90 \pm 1.5\%$ Fig. 3.

Clinical history revealed the presence of daytime fatigue more so than daytime sleepiness, poor sleep, and difficulty in school due to poor concentration and attention span. Less frequently ($n = 18$), there was a positive history of parasomnias. On clinical evaluation, all cases had an abnormally “long face” with an elongated lower facial third in addition to an abnormally narrow hard palate. In some cases, parents were hesitant to consider the possibility of abnormal breathing during sleep. This is likely due to poor recognition of abnormal facial features associated with SDB in the dentist-orthodontist and pediatric communities. The association between congenitally missing teeth and facial skeletal changes with “straight to concave profile, pointed chin, reduced lower facial height and altered dental inclination” was already noted by Ben-Bassat and Brin (2009) [14] but these authors did not investigate breathing during sleep.

Genes, facial growth and alveolo-dental synchondroses (see Table 1)

Embryologic development and craniofacial studies have shown that at least one Homeobox gene [15], the muscle segment homeobox gene (*Msx1*), is involved in early embryological development of the facial aspects derived from the neuro-ectodermal stratus. While this gene is very active early in development, its

Missing 6 upper teeth, missing 5 lower teeth

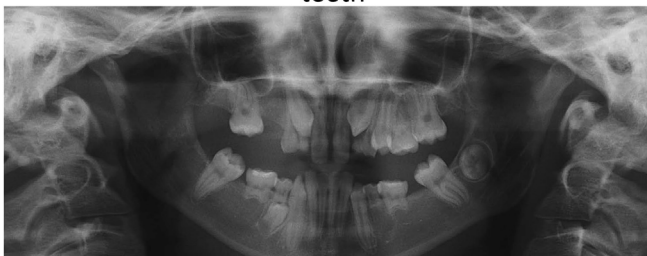

Fig. 3. Agensis of teeth related to gene mutation in a child that developed SDB. This simple dental X-rays show the many absent teeth related to mutation. The child has an apnea–hypopnea-index (AHI) of 3.8 with a much higher AHI in rapid-eye-movement-REM-sleep. Flow limitation defined with nasal cannula – pressure transducer, leading to important daytime fatigue and large and abnormal amount of cyclic-alternating pattern with abnormal amount of phase A2 and A3 during non-rapid-eye-movement – NREM-sleep indicative of sleep-disruption, is present during 71% of total sleep time. SDB: sleep-disordered breathing.

expression becomes more limited in “progenetrical cells,” controlling proliferation and differentiation of cells involved in formation of the craniofacial skeleton.

Msx1 controls proteins diffusing outside the cell, such as growth factors, particularly the bone morphogenetic protein (BMP4) that also has an inductive role on *Msx1* expression. Overexpression of *Msx1* keeps bone and odontoblastic cells in an undifferentiated state. *Msx1* controls specific cell populations, particularly the amount of mother cells involved in the formation of bones. Mutations of *Msx1* are associated with presence of dys-genesis such as in Pierre Robin syndrome, a syndrome associated with SDB. The *MSX1* and *PAX9* proteins are highly correlated and the presence of mutations in these genes has been considered to lead to a haploinsufficiency (i.e., reduced amount of functional protein) allowing occurrence of abnormalities in odontogenesis [16]. The genes homeobox *LHX 6/7* and *Gsc* are also involved in placement of the odontogenic cells and control the growth factor *FGF8*. This growth factor, through induction of a protein (*Lf7*), inhibits *Gsc*, and then the *DLXs* genes [13] induce odontogenesis, as do the genes *LHX 6/7*.

The *DLX* genes, as mentioned above, were well studied in mice [11] and shown to cause specific mutations altering dental development. In humans, the *DLX* genes are located on chromosome 7, showing a similar dental homeocode as that existing in mice. This dental homeocode, deciphered by Thomas and Sharpe [13], shows a link between specific dental agenesis and certain mutations of or elimination of one of these genes. For example, absence of *DLX1* and *DLX2* leads to absence of molars in the maxilla, and mutations of *DLX 5* and *6* lead to absence of inferior molars. Other genes have been associated with dental agenesis and: Mutations on *Pax 9* on chromosome 14 is associated with variable forms of oligodontia that mainly affect the molars and mutations involving *AXIN2*, *WTA10*, *EDA* genes have also been associated with hypodontia [8,14,17–25]. But potentially many other genes could be involved as several hundreds – up to 200-have been mentioned as directly or indirectly involved in the regulation of tooth development [14,23]. Table 1 indicates the major families of genes that may be associated with genetic mutations leading to abnormal odontogenesis.

Dental research has shown that tooth agenesis is a common congenital disorder, it may be associated with syndromes but it is also often seen in non-syndromic children and its prevalence has been variable depending of authors but findings oscillate between 10 and 20% of the studied population [20]. Most commonly only one tooth is agenetic but in 10% of the agenetic cases two are involved with the 2nd premolar and the lateral incisive being considered as more frequent agenesis and 1–2% having oligodontia.

In our children recognized with SDB there were at least two agenetic teeth. The clinical presentation was not obvious as snoring was not a chief a symptom as the more regularly mentioned mouth breathing [26]. During infancy, they were crying infants labeled as having colic, sleep disruption, poor development of long sleep phase with circadian clues [27] and difficulty in feeding. When older, the children and their parents, complained of daytime fatigue, impaired attention and focus in school, and poor and disrupted sleep more so than daytime sleepiness [28]. Clinical evaluation outlined presence of a high and narrow hard palate and an asymmetrical development most often involving the lower third of the face and frequently associated with a counter-clockwise rotation of the mandible. Evaluation of the upper airway shows an abnormal Friedman–Mallampati scale score [29,30] of 3 or 4 and a high and narrow hard palate associated with a narrow maxilla with or without cross-bite. A deviated septum and mouth breathing are commonly found in association with a high and narrow hard palate, likely from hard palate elevation. The most significant PSG finding was the degree of flow limitation [10,11] during total sleep

Table 1
Missing teeth and genes identified with occurrence of small upper airway in syndromic and non-syndromic children.

Genes and teeth: Between 70 and 200 genes are involved in the development of normal teeth
Some specific genetic mutations have been identified leading to syndromic (at least 60 syndromes) and non-syndromic absence of permanent teeth

Two genes play a key role in odontogenesis and interact with many other genes: the muscle-segment-homeobox-1 (MSX1) gene and the paired-box-9 gene (PAX9). MSX1 is a regulatory gene and PAX9 is a developmental control gene. They have a very strong interaction between themselves, and interact with many other proteins
Mutations in these genes lead to both syndromic and non-syndromic presentations
Example: a mutation in MSX1 is present with Pierre-Robin syndrome, and in the Witkop tooth and nail syndrome
Example of mutation without syndromic presentation: mutation in PAX9 leads to “Hypodontia” (more than 6 missing teeth); mutation in Arg-31-Pro [homeodomain of MSX1] leads to absence of maxillary 1st premolar, maxillary and mandibular 2nd pre-molars and 3rd molars; mutation in the tumor necrotic factor of the homology domain of the Ectodysplasin A is associated with absence of maxillary incisors and canines

Other important genes involved in odontogenesis:
Signaling molecules: these molecules, binding to the cell-surface receptors, activate specific transcription factors. They direct expression or repression of specific sets of genes controlling cell behavior
And key-signaling molecules are often *growth factors:* four families of growth factors are highly involved in orofacial development
-Fibroblast growth factor (examples: mutations leading to Appert syndrome, Kallman syndrome, scraniosynostosis, all syndromes with small upper airway)
-Hedgehog and Sonic Hedgehog (SHH) (examples: mutations leading to Gorlin-Goltz Syndrome associating oligodontia, clefts and nevoid basal cell carcinoma)
-Wingless (WTT) (example: mutation leading to oligodontia and colo-rectal cancer, but also to non-syndromic lack of superior lateral incisors and small upper airway (particularly mutation on Axis-inhibition-protein-2 [AXIN2])
-Transforming-growth-factor-beta (TGF-beta) [examples: mutations of bone morphogenetic protein (BMP)] and activins (associated with orofacial-digital syndromes, orofacial clefting syndromes, and dental agenesis with, in decreasing frequency, 3rd molars, mandibular 2nd premolars, maxillary lower incisors, and lower central incisors agenesis.)

Mutations in genes of these different families may be associated with syndromic and non-syndromic (involving only teeth agenesis) orofacial development

Dental agenesis either part of a syndromic presentation or isolated and limited to dental agenesis, are associated with changes in maxillar and/or mandibular growth
This abnormal growth is a risk-factor for small upper airway and increased collapsibility during sleep

time more so than the AHI. There was a progressively increasing AHI with age, with this latest finding suggesting perpetual worsening after birth with age.

Our cases demonstrate the important role of abnormal craniofacial growth in the development of pediatric SDB and involvement of synchondroses particularly those still active during childhood.

Craniofacial muscle activity, genes and abnormal orofacial growth

There is an interaction between muscle activities, particularly those of the face, and growth and normal development of the upper airway. Genetic abnormalities impairing normal activity of striatal muscles, including facial muscles, lead to SDB. The most studied genetic disorder involving mutations and generalized muscle impairment is myotonic dystrophy, both type I and type II [31]. The impact of abnormal facial muscle contractions present in myotonic dystrophy on the development of SDB in children was investigated

and demonstrated many years ago. The studies showed a progressive worsening in AHI from the teenage years to adulthood. There was also increased worsening of daytime sleepiness documented by a multiple nap test; clinical features included presence of a long face and a high and narrow hard palate. The deduction from these studies is that the abnormal activity of muscles controlling the craniofacial structures also has an impact on the development of the naso-maxillary complex and the mandible leading to a small upper airway. Myotonic dystrophy is again related to genetic mutations that are already present during fetal life. Other genetic mutations that diffusely impact all muscles in the body may also lead to SDB, again due to impairment of normal facial muscle functioning: in our own clinical pediatric cases, Duchenne dystrophy was also associated with high narrow hard palate and with a combination of obstructed breathing and respiratory problems related to muscle weakness during sleep. Training in breathing and facial muscle activity is present during fetal life as demonstrated by ultrasonography [32], so abnormalities of craniofacial growth related to muscle impairments due to genetic mutations may begin in-utero.

Environmental impairment of orofacial muscle activity

Experiment done by Harvold et al. involving monkeys [33], demonstrates that non-genetic postnatal impairment may also have a similar impact as genetically induced muscle impairment. Between 1980 and 1990, a number of ground-breaking experiments on newborn rhesus monkeys were performed, whereby a small silicone head was placed within the nostrils of infant monkeys and held in place by a thin thread in order to induce nasal resistance for the first six months of life [33–36]. The blockage of the nasal passages led to narrowing of dental arches, decrease in maxillary arch length, anterior cross-bite, maxillary overjet, and increase in anterior facial height [33–35]. Experimentally induced abnormal nasal resistance led to systematic changes in the orofacial muscles. The changes were noted in the recording of different muscles, in particular the geniohyoid, the genioglossal muscles of the tongue, the suprahyoid dorsal tongue fibers, the upper lip elevators, and the digastric muscles. EMG testing showed abrupt induction of rhythmic discharge patterns, a stark contrast to the nearly continuous and desynchronized discharges in most normal subjects. Tonic EMG discharges reverted back to the normal pattern when nasal breathing was restored at the end of the six-month experiment [34]. These experiments demonstrate that impairment of certain normal functions impact normal craniofacial growth. In this particular study, impaired nasal breathing had an impact on the inter-maxillary suture (as do mutations seen in Ehlers Danlos syndrome [9]), and secondary mouth breathing also had an immediate impact on the mandibular condyle position. This experimental manipulation impacting tongue and facial muscle activities consequently leads to craniofacial growth impairment and mouth breathing which narrows the size of the upper airway and further deteriorates normal nasal breathing, particularly during sleep.

The experimental data show presence of a continuous interaction between abnormal nasal resistance and orofacial growth through the intermediary of abnormal muscle tone and mouth breathing (with a change in the mandibular condyle position). The abnormal growth leads to further worsening of the nasal resistance. The consequence is a small upper airway.

In children, prematurity is often associated with generalized muscle hypotonia. Its severity is dependent on degree of prematurity. In our follow-up cohort of 400 premature infants born as early as 27 wk of gestational age, initial evaluations of 292 of these infants indicated progressive development of obstructive breathing during sleep. This was in spite of the disappearance of the

diaphragmatic apneas of prematurity [37]. This atypical breathing pattern was associated with the development of mouth breathing and a high and narrow hard palate. Early premature infants have often abnormalities involving feeding functions such as suction, mastication, and swallowing with weakness of orofacial muscles that negatively alter the craniofacial growth, and lead to small upper airway.

Full term children are also at risk due to abnormal functional behavior early in life. These infants have no identifiable genetic or neurological disorder and have a normal oto-laryngological evaluation but are found to have abnormal mouth breathing or mild feeding difficulty despite a normal growth curve. Subsequent PSG in this subset of infants has shown flow limitation and a low but abnormal AHI with disrupted nocturnal sleep during the first six weeks of life [37]. It is possible that these infants have an unrecognized genetic problem despite thorough clinical evaluation, but the abnormal functional behavior, including the presence of mouth breathing during sleep, was the only evidence of increased risk for SDB. This suspicion was confirmed by PSG done in the ensuing 10 mo that showed a slow but progressive increase in flow limitation and secondary development of snoring sounds.

Some muscle activity limitations are easily recognized at birth such as the presence of a short anterior frenulum leading to abnormal feeding behavior and speech development. All our children with short mandibular frenulum had an association with SDB when seen untreated between two and six years of age. They all had a narrow and high hard palate Fig. 4.

Environmental impairment of the alveolo-dental synchrony

Dental agenesis may be related to infection (e.g., rubella), chemotherapy, radiation or toxic substances (Thalidomide) [38], Schalk-van der Weide et al. [39] reported impact of extraction of temporary teeth and secondary permanent dental agenesis. We have studied a small group of 11 children with permanent teeth extraction (mostly second molar or lateral incisor) between age 10 and 13 y who developed symptoms of SDB within five years associated with abnormal maxilla-mandibular growth and small upper airway.

Environmental impairment of the temporo-mandibular articulations and development of SDB

Chronic inflammatory diseases, such as rheumatoid juvenile arthritis, that lead to impairment of temporo-mandibular articulation leads to post-natal abnormal craniofacial growth with again progressive development of small oral cavity and presence of a high and narrow hard palate. In our children we observed presence of abnormal breathing during sleep as early as two-years of age associated with poor sleep [40]. Trauma on temporo-mandibular articulation has similar impact: in our own data-base we have three teen-agers with unilateral trauma that led to secondary impairment orofacial growth, narrow oral cavity, daytime fatigue and sleepiness and typical sleep-disordered breathing.

The above findings imply that there are pathways at play placing children at increased risk of development of SDB abnormal functional behavior during wake and sleep associated with craniofacial growth. There appears to be a continuous interaction between function and development involving the craniofacial region. Impairment of growth due to genetic mutations, environmental factors, and interaction between environmental factors and genes (epigenetics), leads to changes in facial growth patterns that influence facial tasks. These functional impairments have a negative feedback on orofacial growth, further impairing functions. The consequence is presence of a reduced upper airway size which in association with sleep leads to SDB.

Short frenulum

- Speech difficulties early in life

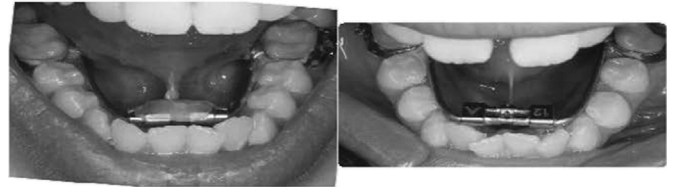

Fig. 4. Frenulum. Example of a short frenulum in a child that presented with speech difficulties early in life and developed sleep-disordered breathing (SDB) associated with a narrow hard palate. The abnormally short structure limits normal movements of the tongue and keeps it in an abnormally low set position when at rest. While the child had orthodontic treatment for his abnormal maxillary growth, the presence of his short frenulum was not recognized. It impaired successful results of orthodontia due to its continued restriction of tongue movements as indicated by persistence of high AHI (apnea–hypopnea index) at PSG (polysomnogram).

Adenoids, tonsils, turbinates, and sleep-disordered breathing

Adenoids and tonsils are secondary or peripheral lymphoid organs that develop during fetal life with lymphoid tissues developing near the fifth week of fetal life [41]. They are the sites of lymphocyte activation by antigens. When activation occurs, there is a clonal expansion and affinity maturation. The mature lymphocytes recirculate between the blood and the peripheral lymphoid organs looking for the specific antigen that they have been matured to target. It is in these secondary lymphoid tissues, specifically the adenoids and tonsils, that the antigen (a foreign or altered native molecule) is placed in contact with the lymphocytes. The specific lymphocytes targeted are primarily in the follicles present in adenoids and tonsils. Reaction against foreign molecules may be related to genetic patrimony, exposure during fetal life, or even due to the temporary interaction between a mother's immune defense system and the infant's own genetic patrimony. An inflammatory reaction will be triggered by the interaction between an antibody and the foreign molecule. This reaction leads to subsequent enlargement of the organ. Viral infections, cysteinyl leukotrienes endogenous synthesis, history of wheezing and familial factors play also an important role in the pathogenesis of adenotonsillar hypertrophy. Nasal turbinates are not similar to adenoids and tonsils, but they are also a site of the allergen and antibody reaction and therefore also swell and enlarge as a result of this effect.

It has been assumed that the enlargement of lymphoid tissues (probably related to the underlying inflammatory reaction discussed above) was directly related to the development of SDB early in life. Systematic evaluation of palatine tonsils in 27–35 wk of age premature infants, however, indicates that tonsils are small early in life [37]. Adenoids could not be investigated in this study, and thus enlargement of adenoids could not be ruled out. It is important to note that children without tonsil and adenoid enlargement as documented by cephalometric X-rays but with dental agenesis also develop SDB in early childhood.

Based on these findings, it appears that adenotonsillectomy may not be the primary treatment modality in preventing the development of SDB. There is a balance between bone and tissue development. The importance of maintaining this relationship has been shown as discussed above, however, postnatally there is also interaction between specialized tissue size and function. Due to fetal processes, an individual may have a naso-maxillary build-up that does not allow a large pharyngeal space [3]. The pharynx relates specifically to the middle cranial fossa and the size of this specific fossa in humans determines the horizontal dimension of the pharyngeal space, and these spatial relationships are

established during fetal life. Any reduction in skeletal dimensions will influence the space allocated for soft tissues. Similarly, enlarged adenoids will lead to impaired nasal breathing depending on the degree of bone development. Inflammatory reactions also play a role in influencing nasal breathing depending on the fetal development of the skull base and craniofacial structures.

Adenoids and tonsils influence function not necessarily because of their absolute size but due to their relative size compared to the available space. Because of their entrapment in a relatively small space due to adeno-tonsil enlargement, soft tissues will also become functionally impaired. If this impairment is counteracted by an increase in tongue and facial muscle activity, there may be no functional deficits of the soft tissue. If, however, this does not occur, the result will be continuous mouth breathing and nasal disuse [26]. Despite this absence of functional deficit, these children will still be vulnerable to sleep disruptions as discussed below. If the compensation is insufficient, there will be progressive development of a complete disuse in nasal breathing, leading to long-term consequences.

In the former situation in which there is adequate compensation of the tongue and facial muscles to offset soft tissue defects, children will not develop mouth breathing; putting them at time at a disadvantage should there ever be abrupt worsening of nasal flow during sleep. In this situation, they will not have the adapted tool of mouth breathing to compensate. This is commonly seen in very young infants where there is an increased effort to breathe nasally and no appropriate mouth breathing. This increased inspiratory effort will lead to increasingly negative intra-thoracic pressures with induction of the Muller maneuver and associated autonomic nervous system changes. Progression of these movements against a partially closed glottis will lead to a significant decrease in the already small tidal volumes of these infants. There will be development of asphyxia and potentially even death as documented on autopsies of infants with abrupt and unexplained deaths during sleep [42,43]. In those with inadequate tongue and facial muscle strengthening to counteract soft tissue impairment, there will be absence of return to normal breathing during sleep post T&A, even with concurrent aggressive nasal allergy treatment. This lack of control of abnormal breathing during sleep post T&A has been well documented in numerous studies of older children [44–49]. Interestingly, long-term prospective follow-up of children who appeared to have significant initial improvement following T&A [50] has shown reoccurrence over time despite absence of abnormal soft tissue in the upper airway. This finding has been confirmed in two retrospective studies [44,45].

There are several reasons why abnormal breathing during sleep in these children post T&A goes unrecognized. Changes in skeletal growth may not be well investigated and at times difficult to recognize by non-specialists. Even if a diagnostic PSG is done, a poor understanding of abnormal breathing patterns during sleep in children may lead to underscoring of respiratory events. Inappropriate or limited usage of tools, such as the esophageal manometry and appropriately calibrated nasal cannula pressure transducers, also hinder appropriate detection of these events. There tends to be too much reliance on oxygen saturation recordings and lack of appropriate investigation of arousal patterns in the sleep electroencephalogram (EEG). Finally, no systematic effort is made to ensure that the functions altered by abnormal breathing during sleep are managed appropriately in order to restore nasal breathing during wake and sleep periods.

There are several questions regarding the development of enlarged tonsils and adenoids. As noted previously, enlarged tonsils in premature children were observed only after documentation of abnormal breathing during sleep and presence of an obstructive

pattern on PSG. Questions then arise whether continuous mouth breathing secondary to impaired nasal breathing leads to lack of appropriate oral humidification and, as a result, a local inflammatory reaction. In addition to changes in humidification, temperature, and air turbulence, there is also micro-trauma related to the mouth breathing itself. Oral breathing also leads to functional changes, including abnormal swallowing, feeding, and occurrence of esophageal reflux. Increasing respiratory efforts affect the diaphragmatic movements causing augmented pressure on the stomach, particularly at feeding times. This may lead to recurrent micro-trauma of the oropharynx and the adenoids with secondary inflammatory reactions. Specialists trained in myofunctional reeducation of infants have documented the need to train young mothers on appropriate positions in which to breast or bottle-feed infants [51]. Finally, in some instances, food or other allergies documented early in life may be present concurrently with inflammatory reactions causing palatine tonsils, adenoids or nasal turbinate enlargement and thereby reducing the upper airway size. A negative cycle then ensues in which impairment of nasal breathing leads to functional impairment, affecting the skeletal growth. This is well documented in experiments done on Rhesus monkeys [33–36].

In summary, it had been previously assumed without complete rationale that enlarged palatine tonsils and adenoids were the major cause of SDB in early childhood. There is a dependent relationship between appropriate nasal breathing and skeletal and soft tissue growth and distribution. Any defect in nasal breathing will affect many fundamental functions during early development and would lead to SDB. To ignore such interactions and focus on what may be the most visually recognizable abnormality, leads to inadequate and limited treatment.

Altering functions to entrain craniofacial growth: role of myofunctional therapy

Problems associated with abnormal nasal breathing were recognized prior to recognition of incomplete treatment with T&A for SDB [52–54]. The understanding of the relationships between function and growth of the craniofacial structures led to experiments on how the honing of the use of these functions would impact the craniofacial growth. Myofunctional therapy done in association with orthodontia and craniofacial surgery has been shown to correct the deficits caused by abnormal growth patterns [55,56]. Myofunctional therapy was developed as a significant tool in Europe in the 1960s. Specialists of the craniofacial sphere recognized the continuous interaction between the facial muscle activity and orofacial development. Individuals such as Delaire in France and Planas in Spain created therapeutic protocols utilizing the stimulation of proprioception and motor activity in the orofacial region in children with craniofacial syndromic presentations and orthodontic problems [55,56]. The extension of these myofunctional therapy protocols to those with SDB is more recent and has been shown to have limited benefit in improving outcomes in some centers. These published trials have been on adults in Brazil [57] and children in France, Northern California, and Taiwan [42,43]. They suggest the possibility of strengthening in function and thus ensuing improvement in SDB. In children, improvement in SDB is accomplished through modification of craniofacial growth. In 2009, Guimares et al. [57] reported on the effects of tongue and facial muscle exercises in adults of age 25–65 y with OSA, with a mean AHI of 22.4 ± 6.48 , i.e., moderate OSA. Outcome measures after three months of approximately 30 min of daily exercises showed not only improved PSG results (with an average AHI score of 13.7 ± 8.5), but also improved scores evaluating sleepiness, snoring, and sleep quality. Compared to the

control group, subjects had significant improvement in all outcome measures.

Huang and Guilleminault [37] studied five premature infants at approximately 36 wk gestational age (GA), including a pair of twins born at 34 wk GA. The patients underwent myofunctional therapy from birth on, and at six months of age, were documented to have normal breathing during wake and sleep verified by nocturnal PSG. They had a normal craniofacial anatomy, normal hard palate, and normal nasal breathing, findings very different from all other studied premature infants who went on to develop obstructive respiratory patterns during sleep. Myofunctional therapy encompassed usage of primitive tongue reflexes to entice the tongue into a specific position. The children sucked on specially designed hard toys and also used a hard rather than soft nipple to feed. In doing so, the premature infants were forced to develop normal suction and swallowing responses. Guilleminault et al. [58,59] reported on the role of myofunctional reeducation in the development of nasal breathing and normal craniofacial development post T&A. These subjects acquired a normal nasomaxillary complex and mandible compared to those non-compliant with the exercise program in the control group. Recent studies have emphasized the importance of normal nasal breathing during sleep, most commonly associated with appropriate craniofacial growth and development of a normal upper airway.

Myofunctional reeducation hones the development of a normal and strong suction, mastication employing both sides of the jaw, normal swallowing, normal tongue position at rest against the upper and posterior face of the upper teeth, and normal nasal breathing with the lips in contact when at rest. The goals of reeducation programs are to eliminate abnormal swallowing, chewing, and speech articulation. They also aim to strengthen the posture and employ continuous usage of the nose when breathing whether the patient is awake or asleep. Reeducation techniques will vary depending on the age of the subject. Myofunctional therapy is applicable to subjects of any age, including premature infants, in whom exercises engage primitive reflexes present at birth. This may include having the infant close their lips around a finger gently placed in their mouth or having them touch their lips at different points in order to draw the tip of their tongue towards the sensory stimulated region [60]. Other techniques include utilizing specific nipples to reproduce the consistency and efforts demanded to pull milk from a mother's breast [61,62] and special toys to aid infants and young children in exploring their tongue and mouth [51]. These modalities should be applied by the parents to their children daily or as often as possible [58–60]. Myofunctional therapy is more advantageous compared to orthodontics in that it can be applied much earlier in life.

The role of obesity in children with sleep-disordered breathing

SDB has been described as a cause of not only poor development but also of failure to thrive. Obesity was not initially a key feature in these first reported cases. With the obesity epidemic beginning in the mid-1990s, increasing number of children were reported to also present with SDB. Certain ethnicities, particularly African American children, have a stronger association between obesity and SDB [63]. Obesity is a complex disorder leading to worsening supine ventilation secondary to restrictive chest-bellows syndrome [63]. This syndrome also leads to progressive fatty infiltration of the neck and upper airway. MRI studies have shown that a progressive fatty infiltration of the genio-hyoid and genio-glossal muscles occurs along with dissociation of muscle fibers with fat cells [64]. These fat

cells also infiltrate the lateral walls of the pharynx in addition to other muscles. Such fatty infiltration leads to enlargement of the soft tissues, reduction in the size of the upper airway, and enlargement of the lingual tonsils. The reduction in tidal volume due to chest restriction from abdominal obesity also leads to mechanical changes that pull the trachea during inspiration. This constant pulling of the hyoid bone during inspiration leads to increased upper airway collapsibility. Obesity can thus result in abnormal breathing during sleep. Obesity is associated with a progressive dysfunction of the adipocyte. Preadipocytes differentiate into mature adipocytes and form adipose tissue in response to a positive energy balance. Adipose tissue not only stores energy, but also acts as a dynamic endocrine organ, vital for hormone and cytokine (adipokine) secretion. White adipose tissue (WAT), located in abdominal and subcutaneous deposits in mammals, performs the majority of energy storage and adipokine secretion [65]. Brown adipose tissue (BAT) mediates the non-shivering thermogenesis, well known to protect infants from cold exposure. Genetics play a role in the control and development of WAT and BAT. Specific animal models of obesity (such as the ob-ob mouse) have been developed showing such genetic role. The differentiation and maintenance of the two types of adipose tissue is interrelated, involving multiple signaling pathways and transcription factors whose expression varies over time. This includes the major genes implicated in WAT and BAT adipogenesis, such as hormones, adipokines, enzymes, transcription factors (particularly PPAR gamma and the C/EBP family), and signal transduction ligands, which are essential in studying the complex interactions between WAT and BAT. Dysfunction of the adipocyte leads to stimulation of adipokines, particularly TNF-alpha and interleukins 6 and 1. These defects lead to pivotal inflammatory responses, both local and general, in addition to abnormal secretion of peptides found not only in the adipocyte but also in the gut and brain. Peptides such as leptin, adinopeptin, obestatin etc., are involved, and dysfunction of the adipocyte leads to leptin resistance and ghrelin dysfunction. These two peptides are crucial in food intake, insulin resistance, and dysregulation of glucose and lipid control [66]. Overweight and obese individuals, with or without SDB, will develop these dysfunctions. The consequences of these abnormalities affect the cardiovascular, respiratory, metabolic, and cerebral systems.

It is clear that the size of the upper airway has an impact on how quick obesity may lead to upper airway impairment and SDB. Initially, a smaller upper airway will have a faster infiltration than larger ones as shown many years ago by Jamieson et al. [67]; but the initial problem is related to two very distinct causes, thus if acute treatment in both cases utilizes positive airway pressure (PAP) therapy, etiogenic treatment and prevention will be very different. Sleep itself may be involved in the development of obesity. Sleep restriction, a consequence of new age electronics in the lives of children, has been shown to have a clear association with the obesity epidemic in children.

Sleep fragmentation, which occurs with abnormal breathing, will cause changes in metabolic controls in part through the process of epigenetics, by which environmental events trigger a genetic cascade that would not have otherwise occurred. Obesity along with the fatty infiltration of upper airway will always lead to SDB from simple flow limitation to frank OSA.

Treatment and prevention of SDB secondary to obesity, however, is very different from the ones in SDB in non-overweight children with impairment of orofacial growth. It is unfortunate that both syndromes are not clearly delineated as the ultimate goal should be prevention of SDB, and this requires a distinct therapeutic approach (Table 2).

Table 2

Overview of factors altering upper airway size that are risk factors for sleep-disordered breathing.

Upper airway

- The nose, naso-pharynx, and oro-pharynx form the upper airway (UA). UA skeletal muscles and soft tissues support respiratory and non-respiratory functions such as sucking, swallowing, and vocalization/phonation.
- The UA can be modeled as a collapsible tube with maximum flow (V_{max}) which is determined by upstream nasal pressure (P_n) and resistance (R_n)
- Upper airway patency depends on the balance between intrinsic collapsibility (P_{crit}) versus the level of pharyngeal muscle dilator activity
- Sleep reduces pharyngeal muscle tone and impairs reflex responses: genioglossus negative pressure reflex is reduced and inhibitory inputs to the genioglossus muscle increase. The change in posture from upright to supine during sleep promotes upper airway collapse.
- Factors that affect upper airway size include the following:
 - Body position: supine posture yields lower lung volumes which result in loss of caudal traction on the upper airway and increased airway collapsibility
 - State of alertness: wakefulness versus sleep (NREM sleep, REM sleep)
 - Respiratory cycle: UA size decreases with decreased lung volume during expiration
 - External factors that reduce UA: fat deposits, hypertrophied tissues, and abnormal craniofacial features.

Factors that affect craniofacial features

- Genetic activity during fetal life
- Persistence of postnatal genetic activity particularly at orofacial growth 'centers'
- External pathological processes disturbing orofacial growth 'centers'
- Orofacial functions

Genetic activity responsible for normal development of tissues supporting the upper airway

- Fetal life: genetic activity at synchondroses is important for normal orofacial development. Impaired craniofacial growth may result from mutations involving many genes that affect development of the brain, skull base, and cranial vault
- Post-natal: Genetic activity persists at the intermaxillary synchondrosis and alveolo-dental synchondrosis. Activity of muscles interacting with active synchondroses also affect normal development
- Genetic mutations may lead to either syndromic or non-syndromic mutations. These mutations may result in abnormal orofacial growth.

Environmental factors that act on orofacial growth centers

- Pathologic processes: inflammatory, traumatic, tumors
- Impairment of normal orofacial functions: sucking, swallowing, chewing, nasal breathing

Interactions of genetic and orofacial structures

- Cranial neural cell crest (CNC) migrates toward developing branchial arches and the subgroup migrates toward specific areas, mixing with mesodermal cells
- The mesodermal cells give rise to muscle cells while CNC cells give rise to nearly all the structures in the head including bones and teeth
- Specialized CNC cells and epithelium continuously interact to cover the face and oral cavity
- Genes acting through proteins control the evolution of different structures in the orofacial region.
 - Mutations in the sequence of one or a group of genes alter expression or function of encoded proteins
 - Environmental factors can also affect expression or normal functioning of protein products
 - Abnormalities lead to orofacial and dental disorders. The result may be either syndromic or non-syndromic

Summary

- Genetic and environmental factors have similar impact on orofacial growth and size of the UA
- Genetic and environmental factors may jointly influence the size of the UA
- Environmental factors may mimic the effects of genetic factors on UA size
- Treatment of environmental factors can reduce/eliminate the negative impact of genetic factors
- Delayed recognition/treatment and further abnormal development of orofacial structures are key factors that reduce the upper airway size and promote secondary development of SDB
- Early recognition of risk factors for abnormal development of orofacial structures allows implementation of preventive measures/interventions

Conclusion

It is important to understand how SDB develops and to separate the SDB seen in obese children from the one observed in non-overweight individuals particularly in its most common presentation of obesity. Understanding the development of the craniofacial structures, their interaction in the growth of the face, and the interaction between specific functions early in life and maxilla-mandibular growth is critical if we wish to prevent development of OSA and eliminate risk of reoccurrence in adulthood. Ultimately, the goal is to provide normal and continuous normal nasal breathing during wake and asleep.

Conflicts of interest

The authors do not have any conflicts of interest to disclose.

Support

No financial support.

Practice points

SDB in children persists and re-occurs after T&A.

Naso-maxillary and mandibular development has an important impact on the size of the upper airway, and any impairment in this development will consequently impact the size of the upper airway.

Development of the facial structure is under the control of genetic and environmental factors.

Two growth centers (synchondroses) are active postnatally (intermaxillary and alveolo-dental) and can be affected further by genetic defects and environment factors.

Treatment of certain environmental factors impacting on the two active synchondroses can avoid development of OSA and be involved in OSA treatment.

Research agenda

It is important to recognize infants at risk of developing OSA. They may be at risk due to genetic or environmental factors which lead to abnormal functioning of the orofacial muscles. Once identified, these infants should undergo myofunctional treatment as early as possible to retrain these muscles. Myofunctional therapy may be implemented by trained therapists, dentists, physicians, or parents taught in the correct techniques of how to administer. Further studies of children of OSA family members need to be done to search for potential mutations of genes involved in embryologic development of the naso-maxillary complex and mandible. These investigations could involve looking for concordant or discordant orofacial development and possibly OSA development in homozygote twins in families with OSA.

Acknowledgment

We thank M Camacho MD, otolaryngol, Stanford Sleep Disordered Clinic for constructing Fig. 1.

References

- [1] Akinin JJ. In: Akinin JJ, editor. *Croissance du massif facial superieur in La croissance cranio-faciale*. Paris: SID Publ; 2007. p. 159–78.
- [2] Bjork A. Sutural growth of the upper face studied by the implant method. *Acta Odontol Scand* 1966;24:109–27.
- [3] Enlow DH, Poston WR. *Facial growth*. 3rd ed. Philadelphia: Saunders; 1990.
- [4] Li KK, Powell NB, Kushida C, Riley RW, Adornato B, Guilleminault C. A comparison of Asian and caucasian patients with obstructive sleep apnea syndrome. *Laryngoscope* 1999;109:1937–40.
- *[5] Delaire J. Les mecanismes de la croissance du squelette facial. In: Chateau M, editor. *Orthopedie dento-faciale- Bases fondamentales Paris (France) Cdp*; 1975. p. 72–124.
- *[6] Akinin JJ. *La croissance cranio-faciale*. Paris: SID Publ; 2007. p. 1–267.
- [7] Abad VC, Serinas PSA, Guilleminault C. Sleep and rheumatologic disorders. *Sleep Med Rev* 2008;12:211–9.
- [8] De Coster PJ, Marks LA, Martens LC, Huyseune A. Dental agenesis: genetic and clinical perspectives. *J Oral Pathol Med* 2009;38:1–17.
- [9] Guilleminault C, Primeau M, Yuen K, Leger D, Metlaine A. Sleep-disordered breathing in Ehlers Danlos Syndrome (a genetic model of OSA). *Chest* 2013;144:1503.
- [10] Hosselet JJ, Norman RG, Ayappa I, Rapoport DM. Detection of flow limitation with a nasal cannula/pressure transducer system. *Am J Respir Crit Care Med* 1998;157:1461–7.
- [11] Lin CH, Guilleminault C. Current hypopnea scoring criteria underscore pediatric sleep disordered breathing. *Sleep Med* 2011;12:720–9.
- [12] Iber C, Ancoli-Israel S, Chesson A, Quan S. *The AASM manual for the scoring of sleep and associated events*. Westchester IL: American Academy of Sleep Medicine; 2007 (revision 2013) 2007.
- [13] Thomas BL, Sharpe PT. Patterning of the murine dentition by homeobox gene. *Eur J Oral Sci* 1998;106(Suppl.):48–54.
- [14] Ben-Bassat Y, Brin I. Skeletal and dental patterns in patients with severe congenital absence of teeth. *Am J Orthod Dentofac Orthop* 2009;135:349–56.
- [15] Vieira AR, MEira R, Modesto A, Murray JC. MSX1, PAX9, and TGFA contribute to tooth agenesis in human. *J Dent Res* 2004;83:723–7.
- [16] Boeira Jr BR, Echeverrigaray S. Dentistry and molecular biology: a promising field for dental agenesis. *Tohoku. J Exp Med* 2012;226:243–9.
- [17] Tavajohi-Kermani H, Kapur R, Sciote JJ. Tooth agenesis and craniofacial morphology. *Am J Orthod Dentofacial Orthop* 2002;122:39–47.
- [18] Lissou JA, Scholtes S. Investigation of craniofacial morphology in patients with Hypo- and oligodontia. *J Orofac Orthop* 2005;66:1197–207.
- [19] Vieira AR, Modesto A, Meira R, Barbosa ARS, Lidral AC, Murray JC. Interferon regulatory factor 6 (IRF6) and fibroblast growth factor receptor 1 (FGFR1) contribute to human tooth agenesis. *Am J Med Genet Part A* 2007;143:538–45.
- [20] Shimizu T, Maeda T. Prevalence and genetic basis of tooth agenesis. *J Dent Sci Res* 2009;45:52–8.
- [21] Han D, Gong Y, Wu H, Zhang X, Yan M, Wang X, et al. Novel EDA mutation resulting in X-linked non-syndromic hypodontia and the pattern of EDA-associated isolated tooth agenesis. *J Dent Res* 2013;92:500–6.
- [22] Mues G, Tardivel A, Willen L, Kapadia H, Seaman R, Frazier-Bower S, et al. Functional analysis of ectodysplasin – a mutations causing selective tooth agenesis. *Eur J Hum Gen* 2010;18:19–25.
- [23] Kouskoura T, Fragou N, Alexiou M, John M, Sommer L, Graf D, et al. The genetic basis of craniofacial and dental abnormalities. *Schw Monatsschr Zahnmed* 2011;121:636–46.
- [24] Van den boogaard MJ, Creton M, Bronkhorst Y, Van der hout A, Hennekam E, Lindout D, et al. Mutations in WNT10A are present in more than half of isolated hypodontia cases. *J Med Genet* 2012;49:327–31.
- [25] Yang Y, Luo L, Xu J, Zhu P, Wang W, et al. Novel EDA p.Ile 260 Ser mutation linked to non- syndromic hypodontia. *J Dent Res* 2013;92:500–6.
- [26] Lee SY, Carillo O, Guilleminault C. Nasal dis-use and persistence of sleep-disordered- breathing during sleep post adenotonsillectomy in children. *Sleep* 2014;37(Suppl.):A 942.
- [27] Coons S, Guilleminault C. Development of sleep-wake patterns and non rapid eye movement sleep stages during the first six months of life in normal infants. *Pediatrics* 1982;69:793–8.
- [28] Guilleminault C, Winkle R, Korobkin R, Simmons B. Children and nocturnal snoring: Evaluation of the effects of sleep related respiratory resistive load and daytime functioning. *Eur J Pediatr* 1982;139:165–171.
- [29] Mallampati SR, Gatt SP, Gugino LD, Desai SP, Waraksa B, Freiburger D, et al. A clinical sign to predict difficult tracheal intubation: a prospective study. *Can Anaesth Soc J* 1985;32:429–34.
- [30] Friedman M, Tanyeri H, La Rosa M, Landsberg R, Vaidyanathan K, Pieri S, et al. Clinical predictors of obstructive sleep apnea. *Laryngoscope* 1999;109:1901–7.
- [31] Guilleminault C, Cummskey J, Motta J, Lynne-Davies P. Respiratory and hemodynamic studies during wakefulness and sleep in myotonic dystrophy. *Sleep* 1978;1:19–31.
- [32] Kurjak A, Stanojevic M, Andonotopo W, Scaccocchio-Duenas E, Azumendi G, Carrera JM. Fetal behavior assessed in all three trimesters of normal pregnancy by four- dimensional ultra-sonnography. *Croat Med J* 2005;46:772–80.
- [33] Harvold EP, Tomer BS, Vargervik K, Chierici G. Primate experiments on oral respiration. *Am J Orthod* 1981;79:359–72.
- [34] Miller AJ, Vargervik K, Chierici G. Experimentally induced neuromuscular changes during and after nasal airway obstruction. *Am J Orthod* 1984;85:385–92.
- [35] Vargervik K, Miller AJ, Chierici G, Harvold E, Tomer BS. Morphologic response to changes in neuromuscular patterns experimentally induced by altered modes of respiration. *Am J Orthod* 1984;85:115–24.
- [36] Vargervik K, Harvold EP. Experiments on the interaction between orofacial function and morphology. *Ear Nose Throat J* 1987;66:201–8.
- *[37] Huang YS, Guilleminault C. Pediatric sleep apnea and the critical role of oral facial growth: evidences. *Front Neurol* 2013;3:184. doi:103399.
- [38] De Coster PJ, Marks LA, Martens LC, Huyseune A. Dental agenesis: genetics and clinical perspectives. *J Oral Pathol Med* 2009;38:1–7.
- [39] Schalk-van der Weide Y, Steen WH, Bosman F. Distribution of missing teeth and tooth morphology in patients with oligodontia. *ASDC J Dent Child* 1992;59:133–40.
- [40] Lopes MC, Guilleminault C, Rosa A, Passarelli C, Roizenblatt S, Tufik S. Delta sleep instability in children with chronic arthritis. *Braz J Med Biol Res* 2008;41:938–44.
- [41] Wetmore RF. Tonsils and adenoids. In: Kliegman RM, Behrman RE, Jenson HB, Stanton BF, editors. *Nelson textbook of pediatrics*. 19th ed. Philadelphia, Pa: Saunders Elsevier; 2011. chapt.#375.
- [42] Rees K, Right A, Keeling JW, Douglas NJ. Facial structure in the sudden infant death syndrome: case-control study. *BMJ* 1988;317:179–80.
- [43] Rambaud C, Guilleminault C. Death, naso-maxillary complex and sleep in young children. *Eur J Pediatr* 2012;171:1349–58.
- [44] Guilleminault C, Partinen M, Praud JP, Quera-Salva MA, Powell NB, Riley RW. Morphometric facial changes and obstructive sleep apnea in adolescent. *J Pediatr* 1989;114:997–1009.
- [45] Tasker C, Crosby JH, Stradling JR. Evidence for persistence of upper airway narrowing during sleep, 12 years after adenotonsillectomy. *Arch Dis Child* 2002;86:34–7.
- [46] Guilleminault C, Li K, Quo S, Inouye RN. A prospective study on the surgical outcomes of children with sleep-disordered breathing. *Sleep* 2004;27:95–100.
- [47] Tauman R, Gulliver TE, Kirshna J, Montgomery-Down HE, O'Brien L, Ivannenko A, et al. Persistence of obstructive sleep apnea syndrome in children after adenotonsillectomy. *J Pediatr* 2006;149:803–8.
- [48] Guilleminault C, Huang YS, Glamann C, Li K, Chan A. Adenotonsillectomy and obstructive sleep apnea in children: a prospective survey. *Otolaryngol Head-Neck Surg* 2007;136:169–75.
- [49] Bhattacherjee R, Kheirandish-Goza L, Spruyt K, Mitchell RB, Promchiarak J, Simakajornboon N, et al. Adenotonsillectomy outcomes in treatment of obstructive sleep apnea in children: a multicenter retrospective study. *Am J Respir Crit Care Med* 2010;182:676–83.
- *[50] Huang YS, Guilleminault C, Lee LA, Lin CH, Hwang FM. Treatment outcomes of adenotonsillectomy for children with obstructive sleep apnea: a prospective longitudinal study. *Sleep* 2014;37:71–80.
- [51] Bahr D. *Nobody ever told me that*. Arlington Tx: Sensory World; 2010. p. 1–423.
- [52] Hawkins AC. Mouth breathing as the cause of malocclusion and other facial abnormalities. *Tex Dent J* 1965;83:10–5.
- [53] Linder-Aronson S. Adenoids. Their effect on mode of breathing and nasal airflow and their relationship to characteristics of the facial skeleton and the dentition. A biometric, rhino-manometric and cephalometro-radiographic study on children with and without adenoids. *Acta Otolaryngol* 1970;265(Suppl.):1–132.
- [54] Mcnamara JA. Influence of respiratory pattern on craniofacial growth. *Angle Orthod* 1981;51:269–300.
- [55] Chauvois A, Fournier M, Girardin F. *Reeducation des fonctions dans la therapeutique orthodontiques*. Paris: S.I.D.; 1991. p. 1–231.
- [56] Planas P. *Rehabilitacion neuro-occlusal*. Madrid (Spain): Salvat Editores SA; 1987. p. 1–289.
- *[57] Guimaraes KC, Drager LF, Genta PR, Marcondes BF, Lorenzi-Filho G. Effects of oropharyngeal exercises on patients with moderate obstructive sleep apnea syndrome. *Am J Respir Crit Care Med* 2009;179:962–6.
- [58] Guilleminault C, Huang YS, Quo S, Monteyrol PJ, Lin CH. Teenage sleep disordered breathing: recurrence of syndrome. *Sleep Med* 2013;14:37–44.
- *[59] Guilleminault C, Huang YS, Monteyrol PJ, Sato R, Quo S, Lin CH. Critical role of myofascial reeducation in sleep-disordered breathing. *Sleep Med* 2013;14:518–25.
- [60] Page DC. “Real” early orthodontic treatment. From birth to age 8. *Funct Orthod* 2003;20. 48(54)-56(48).
- [61] Ogaard B, Larsson E, Lindsten R. The effect of sucking habits, cohort, sex, inter-canine arch widths, and breast or bottle feeding on posterior cross-bite

* The most important references are denoted by an asterisk.

- in Norwegian and Swedish 3-year-old children. *Am J Orthod Dentofac Orthop* 1994;106:161–6.
- [62] Paunio P, Rautava P, Sillanpaa M. The Finnish Family Competence Study: the effects of living conditions on sucking habits in 3-year-old-Finnish children and the association between these habits and dental occlusion. *Acta Odontol Scand* 1993;51:23–9.
- *[63] Redline S, Tishler PV, Schluchter M, Aylor J, Clark K, Graham G. Risk factors for sleep-disordered breathing in children. Associations with obesity, race, and respiratory problems. *Am J Respir Crit Care Med* 1999;159:1527–32.
- [64] Schwab RJ, Pasirstein M, Pierson R, Mackley A, Hachadoorian R, Arens R, et al. Identification of upper airway anatomic risk factors for obstructive sleep apnea with volumetric magnetic resonance imaging. *Am J Respir Crit Care Med* 2003;168:522–30.
- [65] Ye J. Emerging role of adipose tissue hypoxia in obesity and insulin resistance (review). *Int J Obes* 2009;33:54–66.
- *[66] Bonsignore MR, Mc Nicholas WT, Montserrat JM, Eckel J. Adipose tissues in obesity and obstructive sleep apnea. *Eur Respir J* 2012;39:746–67.
- [67] Jamieson A, Guilleminault C, Partinen M, Quera-Salva MA. Obstructive sleep apneic patients have cranio-mandibular abnormalities. *Sleep* 1986;9:469–77.