

## Influence of Mouth Breathing on the Dentofacial Growth of Children: A Cephalometric Study

Bahija Basheer<sup>1</sup>, K Sundeep Hegde<sup>2</sup>, Sham S Bhat<sup>3</sup>, Dilshad Umar<sup>4</sup>, Kusai Baroudi<sup>5</sup>

### Contributors:

<sup>1</sup>Faculty, Department of Pediatric Dentistry, Al-Farabi College of Dentistry, Riyadh, Saudi Arabia; <sup>2</sup>Professor, Department of Paedodontics, Yenepoya Dental College, Mangalore, Karnataka, India; <sup>3</sup>Vice Principal, Professor and Head, Department of Paedodontics, Yenepoya Dental College, Mangalore, Karnataka, India; <sup>4</sup>Assistant Professor, Department of Orthodontics and Dentofacial Orthopedics, Century International Institute of Dental Sciences and Research Institute, Poinachi, Kasargod, Kerala, India; <sup>5</sup>Faculty, Department of Restorative Dental Sciences, Al-Farabi College of Dentistry, Riyadh, Saudi Arabia.

### Correspondence:

Dr. Basheer B, Department of Pediatric Dentistry, Al-Farabi College of Dentistry, Riyadh, Saudi Arabia. Email: [uniquefemme@gmail.com](mailto:uniquefemme@gmail.com)

### How to cite the article:

Basheer B, Hegde KS, Bhat SS, Umar D, Baroudi K. Influence of mouth breathing on the dentofacial growth of children: A cephalometric study. *J Int Oral Health* 2014;6(6):50-5.

### Abstract:

**Background:** The involvement of mouth breathing, facial, and structural growth alterations, especially during childhood has been discussed in medical and dental literature. The relevance of airway obstruction and its assumed effect on facial growth continues to be debated.

**Materials and Methods:** This study was aimed at assessing the dental and soft tissue abnormalities in mouth breathing children with and without adenoid hypertrophy. Fifty children aged between 6 and 12 years following otolaryngological examination were divided into three groups: Group I (MBA): Twenty mouth breathing children with enlarged adenoids and 60% of nasopharynx obstruction; Group II (MB): Twenty mouth breathing children without any nasal obstruction; Group III (nasal breathers [NB]): Ten nose breathing healthy individuals (control group). Digital lateral cephalograms were obtained and the dental and soft tissue parameters were assessed using the cephalometric software, Dolphin Imaging 11.5 version. Comparison was done using one-way ANOVA and post-hoc analysis.

**Results:** There was a significant increase in IMPA ( $P = 0.001$  and  $0.007$  respectively), interlabial gap ( $P = 0.007$  and  $0.002$  respectively) and facial convexity ( $P < 0.001$  and  $0.001$  respectively) in both MBA and MB groups when compared to NB. The upper incisor proclination ( $P = 0.012$ ) and facial convexity ( $P = 0.003$ ) were significantly higher in mouthbreathers with adenoid hypertrophy. However, upper incisor proclination ( $P = 0.009$ ) was statistically significant only in group MB when compared to NB.

**Conclusion:** All subjects with mouth-breathing habit exhibited a significant increase in lower incisor proclination, lip incompetency and convex facial profile. The presence of adenoids accentuated the facial convexity and mentolabial sulcus depth.

**Key Words:** Cephalometric, dentofacial growth, mouth breathing

### Introduction

Respiration is one of the body's vital functions and under physiological conditions, breathing takes place through the nose. The mouth-breathing syndrome (MBS) is when a child has mixed breathing i.e., the nose is supplemented by the mouth.<sup>1</sup>

Exclusively oral breathing patterns are rare or non-existent. MBS is characterized by disorders of speech organs and joints due to the predominately oral breathing pattern, generally combined with facial deformities, abnormal positioning of teeth and body posture, and with the potential to progress to cardiorespiratory and endocrine disease, sleep and mood disorders and poor performance at school. Furthermore, MBS is related to genetic factors, unhealthy oral habits and nasal obstructions of varying severity and duration.<sup>1</sup>

### Nasal obstruction and facial morphology

Hypertrophy of the adenoids and palatine tonsils is the second most frequent cause of upper respiratory obstruction and, consequently, mouth breathing in children. Prolonged mouth breathing leads to muscular and postural alterations which, in turn, cause dentoskeletal changes.<sup>2</sup> The typical features considered characteristic of persons who have difficulty breathing through their nose and therefore may be diagnosed as having nasal obstruction, is exemplified by the long-face syndrome. The pediatrician often refers to this as "adenoidal facies." The prototype of this condition is considered to include an increase in lower facial height, lip apart posture, narrow alar base, and frequently self-reported "mouth breathing." Intraorally, the clinician might expect to find a narrow maxillary arch with a high palatal vault and a posterior cross bite with a Class II dental malocclusion.<sup>3</sup>

Lymphoid tissue usually develops quickly after birth; it reaches peak size during early childhood and start to regress at around 8 or 10 years of age. In some children, its overgrowth may cause obstruction in the pharyngeal air tract, which may lead to respiratory, sleep, feeding, speech and swallowing disorders. The presence of any upper airway obstruction (such as nasal - sinus pathologies or hypertrophy of Waldeyer's lymphatic ring) can lead to the patient to breathe through the mouth. Oral respiration creates an imbalance in the forces exerted by the lips cheek and tongue; thereby

leading to morphological and growth-related changes in the craniofacial complex.<sup>4</sup>

This study was conducted to assess the dental and soft tissue abnormalities in mouth breathing children with and without adenoid hypertrophy.

### **Materials and Methods**

The present study was conducted in the Department of Pedodontics and Preventive Dentistry, Yenepoya Dental College on growing children who came for dental treatment were referred to the ENT Outpatient Department of Yenepoya Medical College, Yenepoya University for evaluation after obtaining consent from the parents. Ethical clearance was obtained from the Ethical Committee, Yenepoya University prior to the study.

Fifty children aged between 6 and 12 years following otolaryngological examination were divided into three groups: 20 Mouth breathing children with enlarged adenoids and having 60% of nasopharynx obstruction (MBA), 20 mouth breathing children without any nasal obstruction. MB and 10 nose breathing healthy individuals (control group).

The children who presented with previous history of orthodontic treatment, oral or nasal surgical treatment or bone deformity and muscular dystrophy; presence of any other abnormal habits; cases with history of birth injuries and past illness and absence of healthy first permanent molars were excluded from the study.

### **Methods**

#### *Assessment of nasal function*

The adequacy of nasal breathing was assessed by asking the children to breathe through their nose for 1 min after putting water in their mouth and by fogging or condensation on mirror which was placed both near nose and mouth simultaneously and referred to the ENT Department where a detailed clinical and physical examination was done. Following which a PA view nasopharynx radiograph was taken to examine the presence of adenoids. The presence of adenoid hypertrophy was confirmed using examination by direct fiberoptic nasopharyngoscopy.

#### *Assessment of dentofacial changes*

The subjects were made to stand in the cephalostat (rotograph plus) with the Frankfort Horizontal plane parallel to the floor and teeth in centric occlusion. Agfa digital X-ray film (8"×10"; speedE) were exposed at 72 kVp, 10 mA for 0.8 s from a fixed distance of 60 inches following the standard technique in the Department of Oral Medicine and Radiology, Yenepoya Dental College.

Cephalometric assessment was made by means of a combination of manual and computerized methods. The anatomic

landmarks of the craniofacial skeleton used for cephalometric analysis are depicted in Figure 1. The anatomic structures were manually digitized; the points were demarcated and the cephalometric values were measured using the cephalometric software, Dolphin Imaging 11.5 version (Patterson Dental Supply Inc.).

The various linear and angular dental measurements and soft tissue measurements were recorded as nasal breathers (NB) and mouth breathers (MBA and MB) for comparison with cephalometric variables of a normal child.

### **Results**

- There was a significant increase in the upper incisor and lower incisor proclination seen in both the mouth breathing groups (Table 1, Graph 1).
- There was a significant increase observed in the depth of mentolabial sulcus, interlabial distance and facial convexity in mouth breathing children. IMPA ( $P = 0.001$  and  $0.007$  respectively), interlabial gap (Table 2, Graph 2 and 3) ( $P = 0.007$  and  $0.002$  respectively) and facial convexity ( $P < 0.001$  and  $0.001$  respectively) were significantly greater in both MBA and MB groups when compared to NB (Table 3).
- It was observed that upper incisor proclination ( $P = 0.012$ ) and facial convexity ( $P = 0.003$ ) were significantly higher in MBA than in MB group. However, upper incisor proclination ( $P = 0.009$ ) was statistically significant only in group MB when compared to NB (Table 3).

### **Discussion**

The dental professionals apprehend that faces of mouth breathers might develop aberrantly, possibly because of the disruption of normal functional relationships caused by chronic airway obstruction and altered path of airway and thereby alter the treatment outcome.

Oral respiration, low tongue posture and elongation of lower anterior facial height are apparent at 3 years of age, but more commonly detected after age five. The deleterious impact of decreased naso-respiratory function is virtually complete by puberty. Hence, the age group 6-12 years is selected for the present study.

The respiratory function and occlusion development relationship is a controversial subject. Authors such as Behlfelt *et al.* (1990)<sup>5</sup> and Fields *et al.* (1991)<sup>6</sup> directly appointed oral breathing as a malocclusion primary factor. Other authors such as Miller *et al.* (1982),<sup>7</sup> Solow *et al.* (1984)<sup>8</sup> and Cheng *et al.* (1988)<sup>9</sup> appointed oral breathing as a neuromuscular unbalancing factor that secondarily could cause or even increase malocclusion. Although studies by Klein (1986)<sup>10</sup> and Shanker *et al.* (1999)<sup>11</sup> found no conclusive proof that nasal respiratory obstruction alters facial growth development, studies from Miller *et al.* (1982);<sup>7</sup> Tourne and

**Table 1: Comparison of dental cephalometric values of three groups using one-way ANOVA.**

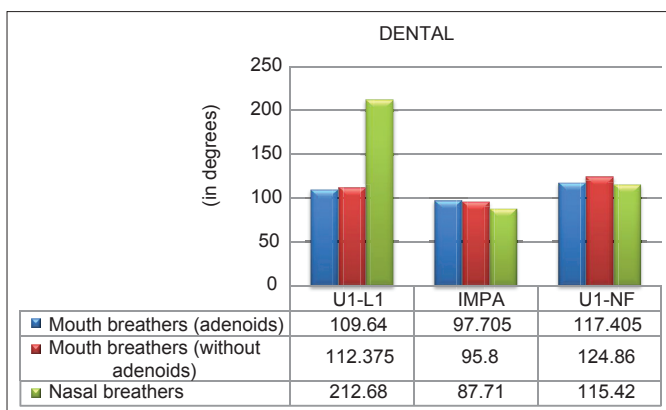
Dental	Groups	N	Mean	Standard deviation	Statistics/mean squares	df <sup>2</sup> (welch)/ F (ANOVA)	P value
Interincisal angle	Mouth breathers (adenoids)	20	109.64	6.50145	1.102	18.912	0.353
	Mouth breathers (without adenoids)	20	112.375	9.59056			
	NB	10	212.68	298.9654			
	Total	50	131.342	134.752			
IMPA	Mouth breathers (adenoids)	20	97.705	5.18992	19.714	29.142	<b>&lt;0.001</b>
	Mouth breathers (without adenoids)	20	95.8	8.61565			
	NB	10	87.71	3.58374			
	Total	50	94.944	7.46166			
U1-NF	Mouth breathers (adenoids)	20	117.405	8.867236	408.416	6.596	<b>0.003</b>
	Mouth breathers (without adenoids)	20	124.86	7.359233			
	NB	10	115.42	6.560623			
	Total	50	119.99	8.721478			

NB: Nasal breathers, All the values marked in bold are statistically significant

**Table 2: Comparison of soft tissue cephalometric values of three groups using one-way ANOVA.**

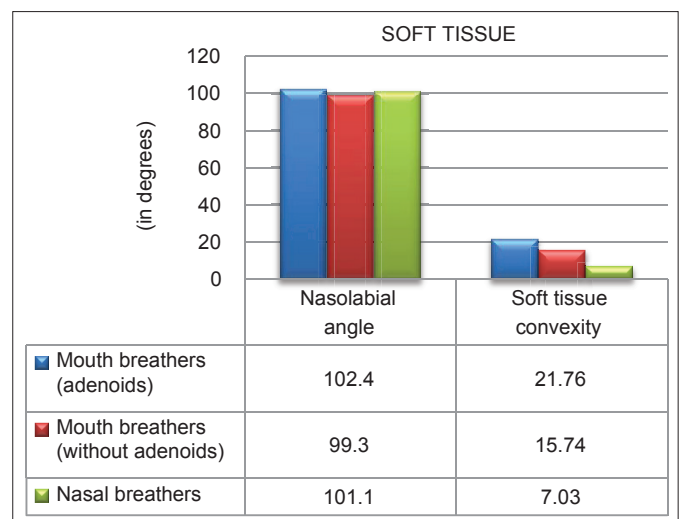
Soft tissue	Groups	N	Mean	Standard deviation	Statistics/mean squares	df <sup>2</sup> (welch)/ F (ANOVA)	P value
Nasolabial angle	Mouth breathers (adenoids)	20	102.46	11.04524	0.787	20.218	0.469
	Mouth breathers (without adenoids)	20	99.285	4.59774			
	NB	10	101.13	8.84685			
	Total	50	100.924	8.48207			
Mentolabial sulcus (in mm)	Mouth breathers (adenoids)	20	3.335	1.858487	11.091	3.925	<b>0.027</b>
	Mouth breathers (without adenoids)	20	2.03	1.614767			
	NB	10	1.88	1.399841			
	Total	50	2.522	1.778476			
Interlabial gap (in mm)	Mouth breathers (adenoids)	20	5.235	3.2613	15.339	30.171	<b>0.002</b>
	Mouth breathers (without adenoids)	20	5.645	2.507562			
	NB	10	1.89	1.479827			
	Total	50	4.73	3.00939			
Soft tissue convexity	Mouth breathers (adenoids)	20	21.76	7.62043	33.195	27.071	<b>&lt;0.001</b>
	Mouth breathers (without adenoids)	20	15.64	3.868143			
	NB	10	7.03	3.300522			
	Total	50	16.366	7.758777			

NB: Nasal breathers, All the values marked in bold are statistically significant



**Graph 1:** Comparison of dental cephalometric values between mouthbreathers and nasal breathers.

Schweiger (1990)<sup>12</sup> call our attention to the studies carried out in human beings in which the oropharynx anatomy and monkey muscles data show that there is a need to exert great care in extrapolating data from experiments with these animals to the human population.



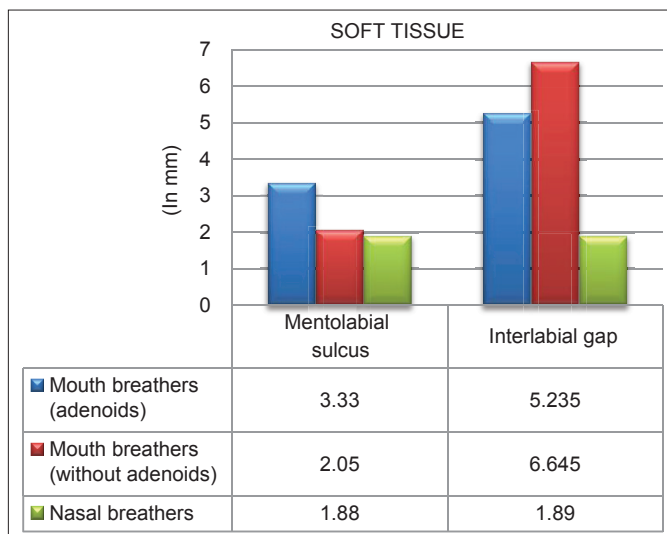
**Graph 2:** Comparison of soft tissue angular cephalometric values between mouthbreathers and nasal breathers

Clinical assessment to visualize indirectly adenoid tissue in children is not easy to be carried out and sometimes it is even

Table 3: Comparison of the cephalometric variables between the 3 groups using *post hoc* analysis.

Tukey HSD						
Dependent variable	(I) V18	(J) V18	Mean difference (I-J)	Standard error	Significant	P value
Dental						
U1-L1	Mouth breathers (adenoids)	Mouth breathers (without adenoids)	-2.735	41.43628	0.998	0.998
		NB	-103.04	50.74887	0.116	0.116
	Mouth breathers (without adenoids)	NB	-100.305	50.74887	0.129	0.129
IMPA	Mouth breathers (adenoids)	Mouth breathers (without adenoids)	1.905	2.0822	0.634	0.634
		NB	9.995	2.55017	0.001	<b>0.001</b>
	Mouth breathers (without adenoids)	NB	8.09	2.55017	0.007	<b>0.007</b>
U1-NF	Mouth breathers (adenoids)	Mouth breathers (without adenoids)	-7.455	2.488404	0.012	<b>0.012</b>
		NB	1.985	3.047661	0.793	0.793
	Mouth breathers (without adenoids)	NB	9.44	3.047661	0.009	<b>0.009</b>
Soft tissue						
Nasolabial angle	Mouth breathers (adenoids)	Mouth breathers (without adenoids)	3.175	2.69909	0.473	0.473
		NB	1.33	3.3057	0.915	0.915
	Mouth breathers (without adenoids)	NB	-1.845	3.3057	0.843	0.843
Mentolabial sulcus	Mouth breathers (adenoids)	Mouth breathers (without adenoids)	1.305	0.531564	0.046	<b>0.046</b>
		NB	1.455	0.651031	0.076	0.076
	Mouth breathers (without adenoids)	NB	0.15	0.651031	0.971	0.971
Interlabial gap	Mouth breathers (adenoids)	Mouth breathers (without adenoids)	-0.41	0.852111	0.881	0.881
		NB	3.345	1.043619	0.007	<b>0.007</b>
	Mouth breathers (without adenoids)	NB	3.755	1.043619	0.002	<b>0.002</b>
Convexity	Mouth breathers (adenoids)	Mouth breathers (without adenoids)	6.12	1.777924	0.003	<b>0.003</b>
		NB	14.73	2.177504	0	< <b>0.001</b>
	Mouth breathers (without adenoids)	NB	8.61	2.177504	0.001	<b>0.001</b>

NB: Nasal breathers, All the values marked in bold are statistically significant



Graph 3: Comparison of soft tissue linear cephalometric values between mouthbreathers and nasal breathers.

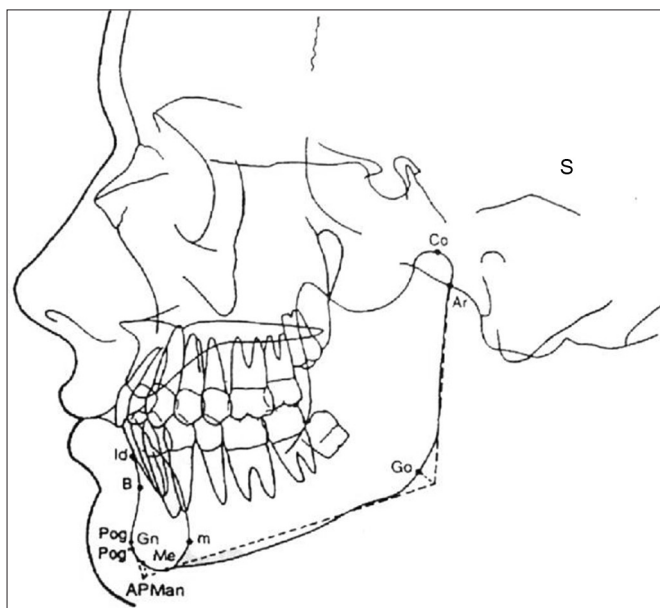
impossible. Therefore, the radiographic image of nasopharynx in profile allows objective, precise and easy measurements. It is paramount that the patient is positioned correctly when performing the radiography; patients should not cry or swallow, because they cause an elevation of the soft palate, giving the impression of obstruction. Adenoid palpation is not a reliable method of measurement, and it is very traumatic for children. Radiological imaging provides more information when compared to palpation. Currently, we have been using the method of visualization of adenoid tissue through endoscopic

exams. This exam provides direct and tridimensional image of nasopharynx and its structures.<sup>13</sup>

In the present study, bimaxillary proclination and upper and lower incisor proclination was seen in the mouthbreathing children. IMPA was significantly higher in both MBA ( $P = 0.001$ ) and MB ( $P = 0.007$ ) when compared to NB. The upper incisor proclination was significant only in the MB group ( $P = 0.009$ ) when compared to the NB (Table 3). The results found in the literature about the inclination of the maxillary and mandibular incisors are controversial because McNamara,<sup>14</sup> Faria *et al.*<sup>15</sup> and Mahony *et al.*<sup>16</sup> concluded that maxillary incisors were protruded in the mouth breathers, justified by interposition of the hypertonic lower lip between maxillary and mandibular incisors provoking labioversion of the maxillary incisors. However, Solow *et al.*<sup>8</sup> Behlfelt,<sup>5</sup> Ung *et al.*<sup>17</sup> and Zettergren-Wijk *et al.*<sup>18</sup> salient that maxillary incisors are found retroclined in these patients in relation to the S-N line and Tarvonen and Koski<sup>19</sup> reported that the mandibular incisors presented retroclination in relation to the mandibular plane in patients with hypertrophic adenoid. Our study showed that patients with adenoid hypertrophy presented with proclined maxillary incisors when compared with mouthbreathers without hypertrophied adenoids.

The soft tissue facial convexity ( $P = 0.003$ ) was significantly higher in MBA than in MB group indicating a more convex profile in the mouthbreathers when compared to the NB (Table 3). This was not in concordance with the findings





**Figure 1:** Landmarks of craniofacial skeleton used for cephalometric analysis. S: Sella – This is the point representing the midpoint of the pituitary fossa (Sella turcica); it is a constructed point in the median plane, Sc: Midpoint of the entrance to the Sella – This point represents the midpoint of the line connecting the posterior clinoid process and the anterior opening of the Sella turcica; it is at the same level as the jugum sphenoidale and it is independent of the depth of the Sella, Po: Porion (anatomic) – The superior point of the external auditory meatus (the superior margin of the temporomandibular fossa, which lies at the same level, may be substituted in the construction of Frankfort horizontal) (bilateral), Or: Orbitale – The lowest point in the inferior margin of the orbit, midpoint between right and left images (bilateral), Na: Nasion – The most anterior point of the frontonasal suture in the median plane (unilateral), Ba: Basion – The median point of the anterior margin of the foramen magnum can be located by following the image of the slope of the inferior border of the basilar part of the occipital bone to its posterior limit (unilateral), Ptm: Pterygomaxillary fissure – A bilateral teardrop – shaped area of radiolucency, the anterior shadow of which represents the posterior surfaces of the tuberosities of the maxilla; the landmark is taken where the two edges, front and back, appear to merge inferiorly, ANS: Anterior nasal spine (or sp) spinal point – This is the tip of the bony anterior nasal spine, in the median plane (unilateral); it corresponds to the anthropological point acanthion; PNS: Posterior nasal spine – The intersection of a continuation of the anterior wall of the pterygopalatine fossa and the floor of the nose, marking the dorsal limit of the maxilla (unilateral); the point pterygomaxillary (ptm), which represents the dorsal surface of the maxilla at the level of the nasal floor, also resembles landmark, PNS A: Point A (or ss, Subspinale) – The point at the deepest midline concavity on the maxilla between the anterior nasal spine and Prosthion (unilateral), B: Point B (or sm, Supramentale) – The point at the deepest midline concavity on the mandibular symphysis between infradentale and Pogonion (unilateral) (Downs), Pog: Pogonion – The most anterior point of the bony chin in the median plane (unilateral), Gn: Gnathion – This is the most anteroinferior point on the symphysis of the chin, and it is constructed by intersecting a line drawn perpendicular to the line connecting Me and Pog; however, it has been defined in a number of ways, including as the lowest point of the chin, which synonymous with menton, Me: Menton – The most inferior midline point on the mandibular symphysis (unilateral), Go: Gonion – The constructed point of intersection of the ramus plane and the mandibular plane, Co: Condylion (or cd) – The most superior point on the head of the condylar head (bilateral), Ar: Articulare – The point of intersection of the images of the posterior border of the condylar process of the mandible and the inferior border of the basilar part of the occipital bone (bilateral).

of Jakobsen *et al.*<sup>20</sup> who found that the soft tissue profile of the children with impaired nasal breathing in general is not different from the soft tissue profile of other orthodontic patients.

The mouth breathing children presented with a higher degree of the lip separation. The interlabial gap was significantly higher in both MBA ( $P = 0.007$ ) and MB ( $P = 0.002$ ) when compared with the control group (Table 3). According to Trotman *et al.*<sup>21</sup> a more open lip posture was associated with a more backwardly

rotated face and larger lower facial height. The increased interlabial gap may also be attributed to the hypotonicity of the upper and lower lip<sup>2</sup> and increased incisor proclination<sup>22</sup> seen in children with mouthbreathing.

The data of this study was related to the standard cephalometric values of Caucasian population. However, various studies have stated that the standard measurement of one group should not be considered normal for other racial groups.<sup>23</sup> Different racial groups should be treated according to their

own characteristics, and it is, therefore, important to develop standards for various population groups.

### **Conclusion**

The present study led to the conclusion that all subjects with mouth-breathing habit exhibited significant lower incisor proclination, lip incompetency and convex facial profile. The presence of adenoids accentuated the facial convexity and mentolabial sulcus depth.

A multidisciplinary team should work to have early diagnosis and appropriate treatment, preventing the consequent disorders of chronic mouth breathing. Because upper airway obstruction is an obstacle to normal dentofacial development, mouth breathing children deserve prompt attention before growth has proceeded irreversibly. The early recognition of such facial patterns may be utilized to identify those breathing compromised individuals who are likely to develop such types of malocclusions.

Hence, a joint effort by pedodontist, orthodontist, otorhinolaryngologist and pediatrician is thus required for reducing continuing detrimental effects of breathing impairments on facial characteristics.

### **References**

1. Abreu RR, Rocha RL, Lamounier JA, Guerra AF. Etiology, clinical manifestations and concurrent findings in mouth-breathing children. *J Pediatr (Rio J)* 2008;84(6):529-35.
2. Valera FC, Travitzki LV, Mattar SE, Matsumoto MA, Elias AM, Anselmo-Lima WT. Muscular, functional and orthodontic changes in pre school children with enlarged adenoids and tonsils. *Int J Pediatr Otorhinolaryngol* 2003;67(7):761-70.
3. Vig KW. Nasal obstruction and facial growth: The strength of evidence for clinical assumptions. *Am J Orthod Dentofacial Orthop* 1998;113(6):603-11.
4. Pereira SR, Bakor SF, Weckx LL. Adenotonsillectomy in facial growing patients: Spontaneous dental effects. *Braz J Otorhinolaryngol* 2011;77(5):600-4.
5. Behlfelt K. Enlarged tonsils and the effect of tonsillectomy. Characteristics of the dentition and facial skeleton. Posture of the head, hyoid bone and tongue. Mode of breathing. *Swed Dent J Suppl* 1990;72:1-35.
6. Fields HW, Warren DW, Black K, Phillips CL. Relationship between vertical dentofacial morphology and respiration in adolescents. *Am J Orthod Dentofacial Orthop* 1991;99(2):147-54.
7. Miller AJ, Vargervik K, Chierici G. Sequential neuromuscular changes in rhesus monkeys during the initial adaptation to oral respiration. *Am J Orthod* 1982;81(2):99-107.
8. Solow B, Siersbaek-Nielsen S, Greve E. Airway adequacy, head posture, and craniofacial morphology. *Am J Orthod* 1984;86(3):214-23.
9. Cheng MC, Enlow DH, Papsidero M, Broadbent BH Jr, Oyen O, Sabat M. Developmental effects of impaired breathing in the face of the growing child. *Angle Orthod* 1988;58(4):309-20.
10. Klein JC. Nasal respiratory function and craniofacial growth. *Arch Otolaryngol Head Neck Surg* 1986;112(8):843-9.
11. Shanker S, Vig KW, Beck FM, Allgair E Jr, Vig PS. Dentofacial morphology and upper respiratory function in 8-10-year-old children. *Clin Orthod Res* 1999;2(1):19-26.
12. Tourne LP, Schweiger J. Immediate postural responses to total nasal obstruction. *Am J Orthod Dentofacial Orthop* 1996;110(6):606-11.
13. Motonaga SM, Berte LC, Anselmo-Lima WT. Mouth breathing: Causes and changes of the stomatognathic system. *Braz J Otorhinolaryngol* 2000;66:373-9.
14. McNamara JA. Influence of respiratory pattern on craniofacial growth. *Angle Orthod* 1981;51(4):269-300.
15. Faria PT, de Oliveira Ruellas AC, Matsumoto MA, Anselmo-Lima WT, Pereira FC. Dentofacial morphology of mouth breathing children. *Braz Dent J* 2002;13(2):129-32.
16. Mahony D, Karsten A, Linder-Aronson S. Effects of adenoidectomy and changed mode of breathing on incisor and molar dentoalveolar heights and anterior face heights. *Aust Orthod J* 2004;20(2):93-8.
17. Ung N, Koenig J, Shapiro PA, Shapiro G, Trask G. A quantitative assessment of respiratory patterns and their effects on dentofacial development. *Am J Orthod Dentofacial Orthop* 1990;98(6):523-32.
18. Zettergren-Wijk L, Forsberg CM, Linder-Aronson S. Changes in dentofacial morphology after adeno-/tonsillectomy in young children with obstructive sleep apnoea – a 5-year follow-up study. *Eur J Orthod* 2006;28(4):319-26.
19. Tarvonen PL, Koski K. Craniofacial skeleton of 7-year-old children with enlarged adenoids. *Am J Orthod Dentofacial Orthop* 1987;91(4):300-4.
20. Jakobsone G, Urtane I, Terauds I. Soft tissue profile of children with impaired nasal breathing. *Stomatologija* 2006;8(2):39-43.
21. Trotman CA, McNamara JA Jr, Dibbets JM, van der Weele LT. Association of lip posture and the dimensions of the tonsils and sagittal airway with facial morphology. *Angle Orthod* 1997;67(6):425-32.
22. Frasson JM, Magnani MB, Nouer DF, de Siqueira VC, Lunardi N. Comparative cephalometric study between nasal and predominantly mouth breathers. *Braz J Otorhinolaryngol* 2006;72(1):72-81.
23. Arunkumar KV, Reddy VV, Tauro DP. Establishment of cephalometric norms for the South Indian (Karnataka) population based on burstone's analysis. *J Maxillofac Oral Surg* 2010;9(2):127-33.